

CBCT EVALUATION AND TREATMENT OF MAXILLARY SECOND MOLAR WITH TWO PALATAL ROOTS

Prateek Singh, Asheesh Sawhny, Richa Singh, Mukta Bansal, Saurabh Sharma , Saurav Paul

Rama Dental College Hospital & Research Centre, Rama University, Mandhana, Kanpur, Uttar Pradesh- India 209217

ABSTRACT

Careful evaluation of the internal anatomy of a root canal is critical for successful endodontic treatment. An additional root or missing canal can lead to treatment failures and poor prognosis. The two palatal canals in the maxillary second molar tooth are rare, and its incidence reported in the literature is less than 2%. The unique anatomy of the maxillary second molar teeth is complex to treat due to its posterior location. Superimposition of the anatomical structures on the radiographs of this region may result in a second palatal root canal undiagnosed. The current case report presents non-surgical re-treatment of maxillary second molar with two palatal roots. CBCT image confirmed the presence of nontreated palatal root. The extra palatal root of the tooth had been treated, and the patient's symptoms resolved. Keywords: Cone beam computed tomography, maxillary second molar, second palatal root.

INTRODUCTION

Major causes of endodontic treatment failures are the presence of microorganisms remaining in incomplete instrumentation, inadequate cleaning, inadequate canal obturation, and untreated root canals (1). Thorough knowledge of root canal morphology and prediction of their possible morphologic variations will help to decrease endodontic failure (1,2). Uncommon root and root canal morphologies associated with molar teeth have been reported in several studies in the literature (3,4). The second maxillary molar often has one canal in each root. It may have two or three mesiobuccal (MB) canals, one or two distobuccal (DB) canals or two palatal (P) canals. The reports on two palatal roots in second maxillary molar teeth are low (5,6). The second palatal root is not easy to confirm radiographically because buccal root canals often superimpose the extra root canal.

This problem can complicate root canal treatment and increase the failure rate. Several reports (7–11) evaluated the morphological variations of the root canal system of the palatal root of the maxillary molars. CBCT is one of the most important diagnostic tools for thoroughly assessing this rare morphology in clinical practice. This report aims to present a

case of a right maxillary second molar with two separate palatal roots and to underline the importance of a thorough evaluation of the anatomy of the root canal before treatment.

CASE REPORT

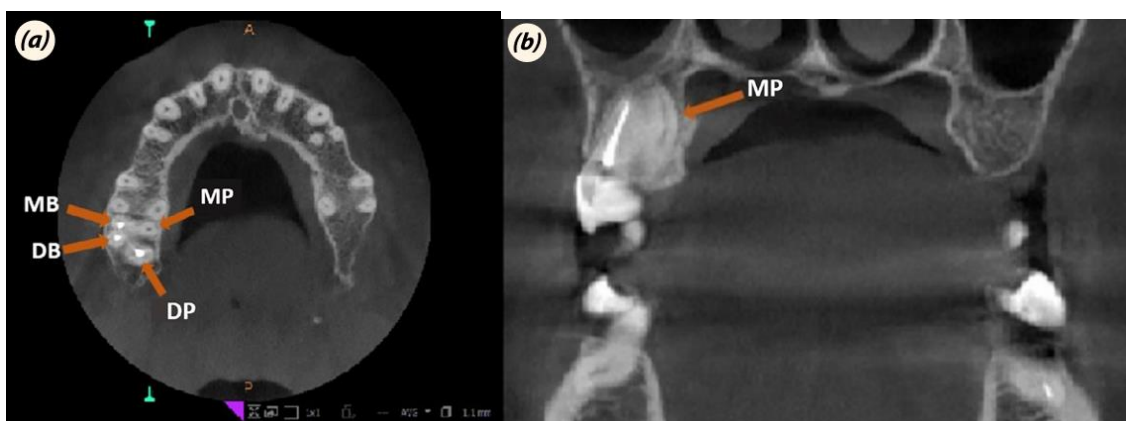
A 33-year-old female patient without medical history reported to the Endodontics Department at Rama Dental College, Kanpur for the upper right second molar with a complaint of spontaneous pain. Clinical examination revealed deep dentine carious lesion, and the teeth were not tender to percussion. After radiological examination, no radiolucency and pathology were detected around the related teeth. Endodontic treatment was planned. The patient was informed about treatment and filled out the consent form. Root canal treatment was performed in the same appointment. One week later, the patient returned to the clinic for spontaneous pain in the same tooth. Clinical examinations revealed that the tooth was tender to vertical percussion and palpation. Vitality tests on the tooth showed a tender response to cold and electric pulp testing. CBCT was taken to understand the cause of the pain. The clinical findings, pulp sensitivity test, radiographic findings, and CBCT led to a diagnosis of irreversible pulpitis with acute apical periodontitis with maxillary right second molar because of a vital second palatal canal (MP) (Fig. 1). Endodontic treatment was planned only for the second palatal canal. The patient was anesthetized with 2% ultracain and 1:80,000 epinephrine. After isolation with a rubber dam, a rhomboidal outlined access cavity was prepared to obtain straight-line access to all canals. There were four canal orifices, three canals (MB, DB, DP), and an extra palatal root canal [mesiopalatal (MP)] located on the floor of the pulp chamber. As the palatal canal was located more distally and a hemorrhagic spot was visible toward the mesial side, confirming two palatal canals (MP, DP). The working length of the MP canal was determined with the apex locator (Root ZX, J. Morita Corp., Tokyo, Japan) and confirmed radiographically. MP canal preparation was performed by ProTaper Next (Dentsply, Ballaigues, Germany) files up to X2 (25/0.06). During instrumentation, the canals were irrigated with 2.5% sodium hypochlorite. MP canal was coated with calcium hydroxide paste (Metapaste, Meta Biomed, Korea), and temporary restoration with Cavit (ESPE GmbH, Seefeld, Germany) was placed. The patient was recalled after one week; the tooth was asymptomatic. MP canal irrigated again with 2.5% NaOCl and normal saline. Before obturation, a master cone radiograph was taken. The final irrigation was accomplished with 2.5% NaOCl and 17% ethylenediaminetetraacetic acid (EDTA) solutions and dried with paper points. The canal was obturated with ProTaper Next X2 gutta-percha cone and AH-Plus sealer (Dentsply DeTrey GmbH, Konstanz, Germany) (Figs. 2 and 3) using the single-cone technique.

DISCUSSION

There are variations in the root canal anatomy of the maxillary second molar, which include a fewer or greater number of roots than commonly described three root forms (12). The prevalence of four rooted (2 buccal and 2 palatal) maxillary second molars is rare; a previous study reported only 0.4% (13). Al Shalabi et al. (14) and Caliskan et al. (8) found the probability of having two palatal foramen in maxillary second molar teeth as 1.2% and 3.23% in their *ex vivo* study. Peikoff et al. (12) reported six variations of a second maxillary molar in their retrospective study as three distinct roots and canals (56%), three separate roots and four canals (two mesiobuccal canals) (22.7%), three roots and canals joining mesiobuccal and

distobuccal canals (9%), two separate roots and canals (6.9%), a single root with one canal (3.1%), and four roots or canals including two palatal canals (1.4%).

The maxillary second molar in this case report has two separate palatal roots and falls into the last group. Although this variation is uncommon, clinicians need to be aware of unusual root canal morphologies and canal configurations. One of the most significant conditions for successful endodontic treatment is adequate knowledge and understanding of root canal anatomy. Adequate knowledge and experimentation can improve the operator's ability to find the additional canal, particularly in the maxillary molars (15,16). The uncommon anatomy of the maxillary second molar teeth is difficult to diagnose due to its posterior location. Superimposition of the anatomical structures on the radiographs of this region may result in a second palatal root canal being undiagnosed. The second palatal canal could not be found radiographically. Although radiographically, it is hard to see extra palatal root/canal, the pulp chamber's shape lets us localize the second palatal orifice. However, the second palatal canal orifice could not localize in the previous root canal treatment because of inadequate access cavity. Undetected extra roots or root canals are the leading cause of root canal treatment failure (17). Thorough knowledge of the root canal system will help to reduce endodontic failures caused by incomplete debridement and obturation. Recently, cone beam/spiral computed tomography (CBCT) scan has been used to diagnose valuable in diagnosing anatomic variations (18–21). CBCT can greatly improve the detection and mapping of root canal systems with the potential to enhance the quality of root canal treatment (22). In summary, this report presented successful re-treatment of a maxillary second molar tooth with two separate palatal roots. CBCT images made it possible to diagnose root canal anatomy. Variation at morphology in teeth is a frequent occurrence, and it is important to know these variations exactly before initiation of endodontic treatment. To diagnose this anatomical variation, careful analysis of the pre-operative radiograph and the pulp chamber floor examination is required.



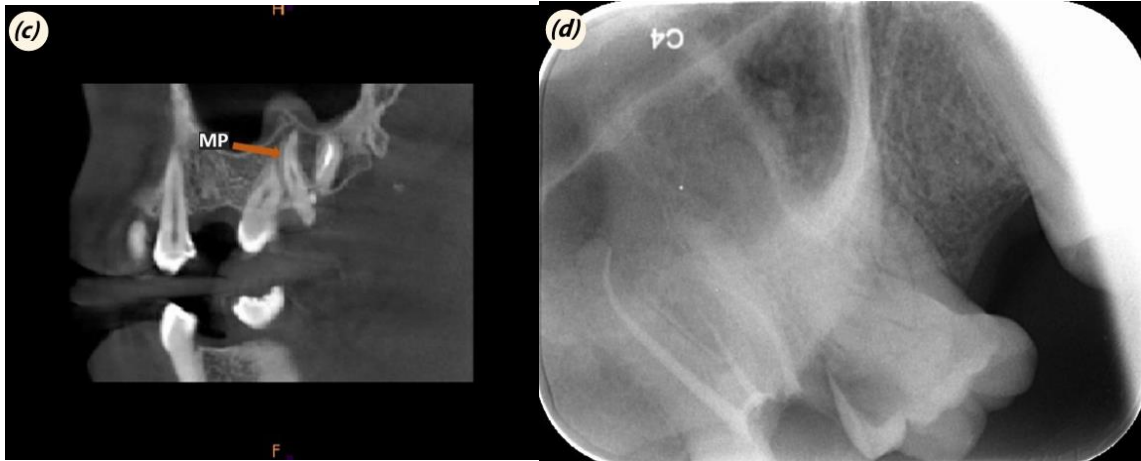


Fig. 1. (a) CBCT axial image of 2nd palatal root of the maxillary second molar. (b) CBCT coronal image of 2nd palatal root of the maxillary second molar. (c) CBCT coronal image of 2nd palatal root of the maxillary second molar. (d) Periapical radiography of 2nd palatal root of the maxillary second molar.




Fig. 2. Access cavity after obturation showing canals orifice sealed with Gutta-percha.

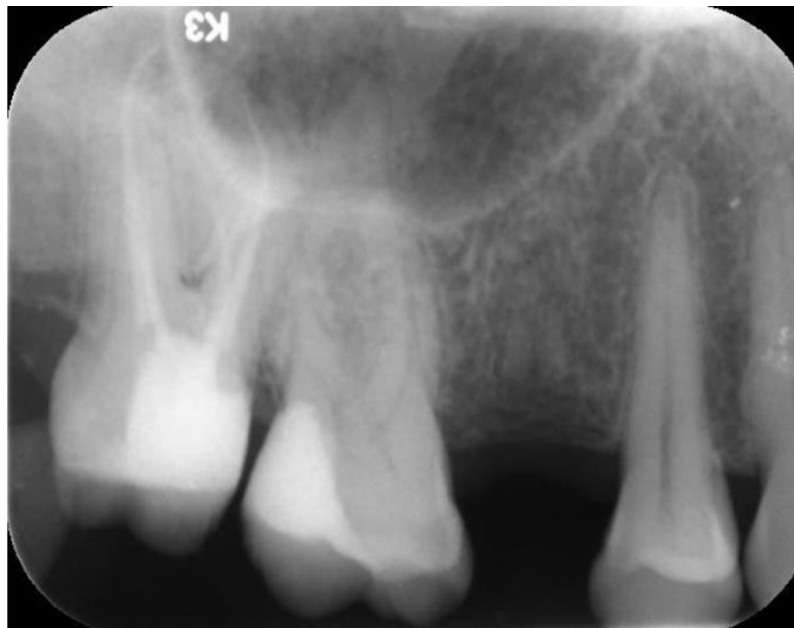

Fig. 3. Postoperative radiograph of root canal obturation.

REFERENCES

1. Siqueira JF Jr, Rôças IN. Clinical implications and micro biology of bacterial persistence after treatment procedures. *J Endod* 2008; 34: 1291–301.e3. [CrossRef]
2. Krasner P, Rankow HJ. Anatomy of the pulp-chamber floor. *J Endod* 2004; 30: 5–16. [CrossRef]
3. Malagnino V, Gallottini L, Passariello P. Some unusual clinical cases on root anatomy of permanent maxillary molars. *J Endod* 1997; 23: 127–8. [CrossRef]
4. Pasternak Júnior B, Teixeira CS, Silva RG, Vansan LP, Sousa Neto MD. Treatment of a second maxillary molar with six canals. *AustEndod J* 2007; 33: 42–5. [CrossRef]
5. Holderrieth S, Gernhardt CR. Maxillary molars with morphologic variations of the palatal root canals: a report of four cases. *J Endod* 2009; 35: 1060–5. [CrossRef]
6. Hülsmann M. A maxillary first molar with two disto-buccal root canals. *J Endod* 1997; 23: 707–8. [CrossRef]
7. Bond JL, Hartwell G, Portell FR. Maxillary first molar with six canals. *J Endod* 1988; 14: 258–60. [CrossRef]
8. Çalışkan MK, Pehlivan Y, Sepetçioğlu F, Türkün M, Tuncer SS. Root canal morphology of human permanent teeth in a Turkish population. *J Endod* 1995; 21: 200–4. [CrossRef]

9. Harris WE. Unusual root canal anatomy in a maxillary molar. *J Endod* 1980; 6: 573–5. [CrossRef]
10. Stone LH, Stroner WF. Maxillary molars demonstrating more than one palatal root canal. *Oral Surg Oral Med Oral Pathol* 1981; 51: 649–52. [CrossRef]
11. Thews ME, Kemp WB, Jones CR. Aberrations in palatal root and root canal morphology of two maxillary first molars. *J Endod* 1979; 5: 94–6. [CrossRef]
12. Peikoff MD, Christie WH, Fogel HM. The maxillary second molar: variations in the number of roots and canals. *Int Endod J* 1996; 29: 365–9. [CrossRef]
13. Libfeld H, Rotstein I. Incidence of four-rooted maxillary second molars: literature review and radiographic survey of 1,200 teeth. *J Endod* 1989; 15: 129–31. [CrossRef]
14. al Shalabi RM, Omer OE, Glennon J, Jennings M, Claffey NM. Root canal anatomy of maxillary first and second permanent molars. *Int Endod J* 2000; 33: 405–14. [CrossRef]
15. Aminsobhani M, Bolhari B, Shokouhinejad N, Ghorban zadeh A, Ghabraei S, Rahmani MB. Mandibular first and second molars with three mesial canals: a case series. *Iran Endod J* 2010; 5: 36–9.
16. Corcoran J, Apicella MJ, Mines P. The effect of operator experience in locating additional canals in maxillary molars. *J Endod* 2007; 33: 15–7. [CrossRef]
17. Slowey RR. Radiographic aids in the detection of extra root canals. *Oral Surg Oral Med Oral Pathol* 1974; 37: 762–72. [CrossRef]
18. Aggarwal V, Singla M, Logani A, Shah N. Endodontic management of a maxillary first molar with two palatal canals with the aid of spiral computed tomography: a case report. *J Endod* 2009; 35: 137–9. [CrossRef]
19. Baratto Filho F, Zaitter S, Haragushiku GA, de Campos EA, Abuabara A, Correr GM. Analysis of the internal anatomy of maxillary first molars by using different methods. *J Endod* 2009; 35: 337–42. [CrossRef]
20. Low KM, Dula K, Bürgin W, von Arx T. Comparison of periapical radiography and limited cone-beam tomography in posterior maxillary teeth referred for apical surgery. *J Endod* 2008; 34: 557–62. [CrossRef]
21. Matherne RP, Angelopoulos C, Kulild JC, Tira D. Use of cone-beam computed tomography to identify root canal systems in vitro. *J Endod* 2008; 34: 87–9. [CrossRef]
22. Zhang R, Yang H, Yu X, Wang H, Hu T, Dummer PM. Use of CBCT to identify the morphology of maxillary permanent molar teeth in a Chinese subpopulation. *Int Endod J* 2011; 44: 162–9. [CrossRef]