

# Experimental Study on Early Bone Fracture Healing in The Rabbit Using Bone Graft Combined with Salmon Calcitonin, Immunohistochemical and Histological Outcomes

Majeed A. A<sup>1\*</sup>, Abdulameer H. H<sup>2</sup>

<sup>1</sup> Al-Nahrain University/ College of Medicine/Iraq  
Email: [Chalabiamani2@gmail.com](mailto:Chalabiamani2@gmail.com)

<sup>2</sup> Al-Nahrain University/ College of Medicine/Iraq.  
Email: [Hh\\_abdulameer@yahoo.com](mailto:Hh_abdulameer@yahoo.com)

\*Correspondence author: Majeed A. A ([Chalabiamani2@gmail.com](mailto:Chalabiamani2@gmail.com))

---

**Received:** 20 January 2023      **Accepted:** 15 April 2023

**Citation:** Majeed A. A, Abdulameer H. H (2022) Experimental Study on Early Bone Fracture Healing in The Rabbit Using Bone Graft Combined with Salmon Calcitonin, Immunohistochemical and Histological Outcomes. History of Medicine 9(1): 1609–1614. <https://doi.org/10.17720/2409-5834.v9.1.2023.199>

---

## Abstract

This study aims to evaluate the histological and immunohistochemical changes after systemic administration of salmon calcitonin with Beta-tricalcium phosphate on fracture healing in rabbits by the quantitative study of the osteoblast's cells at different stages of early bone healing using osteocalcin antibody. Histological findings for the bone healing process in the treated group with  $\beta$ -tricalcium phosphate and salmon calcitonin showed early bone marrow, trabecular bone, mineralization, and compact bone formation in comparison to the healing process in the control group. Immunohistochemical findings expression of anti-osteocalcin revealed that there was a non-significant value in the control group between (2 weeks mean+SD  $0.27\pm 0.06$  and 4 weeks mean+SD  $0.29\pm 0.06$ ). while the treated group with  $\beta$ -tricalcium phosphate and salmon calcitonin showed highly significant differences at (2 weeks mean+SD  $0.5\pm 0.05$  and 4 weeks mean+SD  $0.73\pm 0.07$ ). The conclusion of this study that salmon calcitonin and  $\beta$ -tricalcium phosphate has a major osteogenesis role for early bone formation in the treated group as compared with the control group.  $\beta$ -tricalcium phosphate and systemic salmon calcitonin 2 IU/kg were more effective in the acceleration of the early bone healing process and enhancement of bone regeneration.

---

## Keywords

(Salmon calcitonin, Beta-Tricalcium phosphate, Osteocalcin).

---

Early Osteogenesis and bone formation are key to treating bone injuries and bone diseases like osteoporosis. Minor bone fractures can recover without surgical intervention, the recovery period can be long and inconvenient (Seokhwan et al., 2021). Calcitonin is a calcitropic peptide produced in the parafollicular cells of the thyroid gland. (Naot and Cornish et al., 2008). Calcitonin's clinical importance derives from its ability to inhibit osteoclasts and increase renal excretion of calcium. Through these processes, bone matrix resorption and serum calcium are both decreased. For these reasons, it is of benefit in the treatment of postmenopausal osteoporosis, Paget disease of bone, emergent hypercalcemia, and analgesic

properties (Matthew and Ishwarlal, 2022). The femur is extremely hard and not easy to break. A broken thigh bone is one of the few simple fractures that can be considered life-threatening because it can cause significant internal bleeding (Moore KL and Agur 2009).  $\beta$ -Tricalcium phosphate ( $\beta$ -TCP) is a popular synthetic bone graft substitute with excellent osteoconductive properties and absorbability. However, its osteoinductive properties are inferior to those of autologous or allogeneic bone (Hironori Sugimoto et al., 2021).  $\beta$ -TCP has high porosity and improved osteoconductive properties with a solubility that is approximately 30-fold higher than that of Hydroxyapatite, making it more bioabsorbable and

convenient for clinical application (Aulakh TS. 2009). Calcitonin hormone is composed of 32 amino acids. Is secreted by parafollicular cells (known as C cells) of the thyroid gland in humans and other chordates (Sekiguchi et al., 2016). In the ultimo pharyngeal body, calcitonin acts to reduce blood calcium ( $Ca^{2+}$ ), opposing the effects of the parathyroid hormone, Its importance in humans has not been as well established as its importance in other animals, its function is usually not significant in the regulation of normal calcium homeostasis. It belongs to the calcitonin-like protein family. Also, Parathyroid hormone, when administered as a daily injection, stimulates bone growth in various species (Costoff A. 2008). Salmon calcitonin (sCT) is an endogenous polypeptide 32 amino acid. sCT is currently formulated as either a sterile solution for intramuscular or subcutaneous injection or as a nasal spray. This drug plays a critical role in both calcium homeostasis and the treatment of bone diseases such as osteoporosis, the management of Paget's disease, and the initial treatment of hypercalcemia (Lee K. et al., 2003). Osteocalcin (OSN), known as bone gamma carboxy glutamic acid containing protein (BGLAP), is a small (49-amino-acid) noncollagenous protein hormone found in bone and dentin, first identified as a calcium-binding protein in chick bone (Qian Z et al., 2021). Osteocalcin specifically produced by osteoblasts was demonstrated to inhibit bone formation and function as a hormone, it is recognized as a multifunctional bone-derived hormone that modulates numerous physiological activities and developmental processes.

## Materials And Methods

This study was performed at Al-Nahrain University College of Medicine from November 2021 to August 2022.

**Design of study:** Experimental study, animal model. A total number of male adult rabbits are forty (40), albino rabbits (*Oryctolagus cuniculus*) are divided into three groups animals (20) for each group, The first control group with no treatment. In the second treated group (experimental group), the animals in this group were injected with a daily dose (2 IU/1kg) of Salmon calcitonin (Miacalcic) in addition to  $\beta$ -TCP that was placed in the hole made by surgical operation. the (10) animals were sacrificed after 2 weeks and the other (10) animals were sacrificed after (4) weeks.

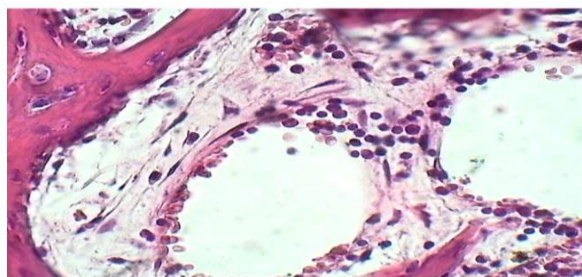
**Surgical operation:** General anesthesia, it was induced with an intramuscular injection of xylazine 20 mg (0.2 ml/kg-B.W.) and ketamine HCL 50 mg (20 mg/kg-B.W.). The site chosen for operation was

the midshaft femoral bone of the lower limb left side. Initial intermittent drilling was done by round bur with a speed 1500 rpm and vigorous irrigation by normal saline, a depth of 2 mm and 3mm in diameter. the diameter was checked by Vernia then application of  $\beta$ -TCP. Each rabbit had systemic administration of antibiotics CEFTRIAXONE vial 500 mg with 5ml solvent ampoule, 0.5cc/kg intramuscular injection, administrated once daily for five days. Afterward, the animals were sacrificed according to each group's healing period. A group of animals was Injected immediately after surgery with this therapy with a daily dose (2 IU/kg) for two weeks and other experimental study groups for four weeks (Theofilos Karachalios, et al. 2009). the animals were euthanized by directly giving an intracardiac injection of pentobarbital an anesthetic drug with an overdose (50 mg/kg) of this medication at (2, 4 weeks) healing intervals.

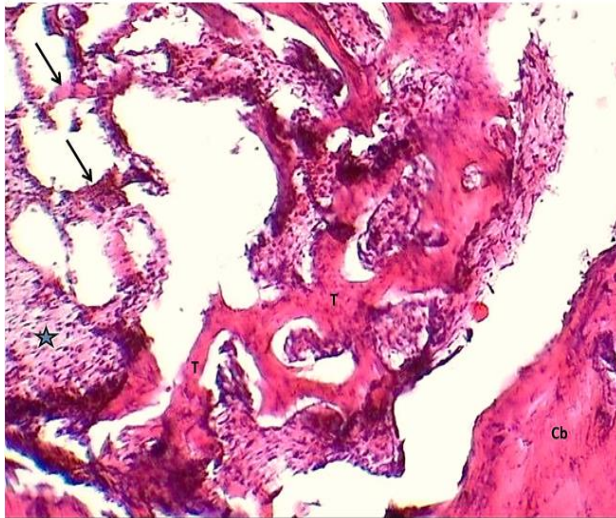
**Tissue preparation:** Embedded tissue section in 10 % formalin. Subsequently, Bone decalcification was accomplished using 10% nitric acid ( $HNO_3$ ) and then the paraffin blocks were sagittally sectioned at a thickness of  $5\mu m$  that were ready to make tissue slides for evaluation of the morphometry, histology, and immunohistochemical study for anti-osteocalcin antibody expression of bone formation statistical analysis were evaluated by image j and a quantitative result of expression of anti-osteocalcin AB.

**Results: Histological findings:** Control group (2 wks): The cross-section of the callus was composed of fibrous tissue rich with fibroblasts in addition to numerous newly formed blood networks (Figure 1).

Treated group with Salmon Calcitonin and Tricalcium Phosphate (2wks): Histological findings showed that the whole revealed well-organized trabecular pattern formation with furthermore mature trabecula, also present remaining of little fibro vascular callus that revealed numerous patches of intramembranous ossification with furthermore newly formed small sizes trabecula (Figure 2).



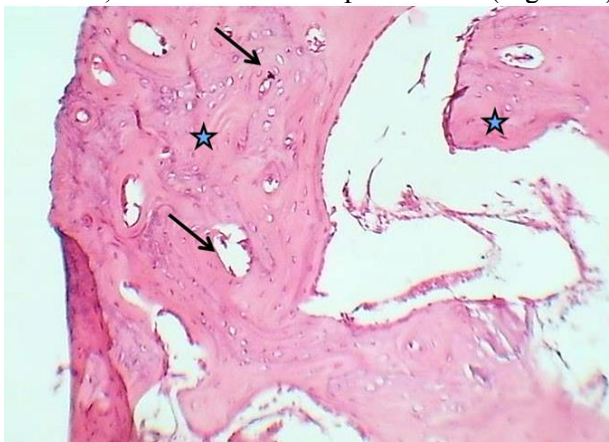
**Figure 1:** Cross section of callus (control group after 2 weeks) shows: fibrous tissue rich with fibroblasts (Black arrows) and newly formed blood network (V) H&E stain.400x.



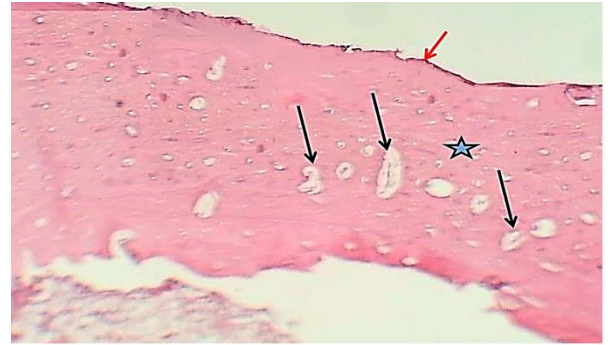
**Figure 2:** Cross section of bone (treated group with Salmon Calcitonin and B-Tricalcium phosphate after 2 weeks) shows: edge of cortical bone (Cb), furthermore mature bone trabeculae (T), newly formed small trabecula (arrows) & little of fibrovascular callus. H&E stain.40x.

Control group(4wks): Histological cross-sections showed that the hole of cortical bone was partially filled with uncomplete ossified bone trabecula that revealed numerous osteoids; the figures revealed not well remodeling of periosteum and endosteum with composed the remnant of the fibrous osteogenic tissue (Figure 3)

Treated group with Salmon Calcitonin and Beta Tricalcium Phosphate Histological cross-sections showed that the hole of cortical bone was filled with ossified osteoid and increased lamellar deposition, which revealed numerous wide Haversian canals outer and inner circumferential lamellae, interstitial lamellae, and well-definite periosteum (Figure 4).



**Figure 3:** Cross section of femur (control group after 4 weeks) shows partially filled hole with ossified bone trabecula (Asterisk) with well-formed osteoid (Arrows) with little of fibrous tissue. H&E stain.100x.




**Figure 4:** Cross section of femur (treated group with Salmon Calcitonin and B-Tricalcium phosphate after 4 weeks) shows: marked well healed bone with increase lamellar deposition (asterisk), with numerous very wide haversian canals outer and inner circumferential lamellae and interstitial lamellae (Black arrows) and well remodeling of periosteum (Red arrows). H&E stain.40x.

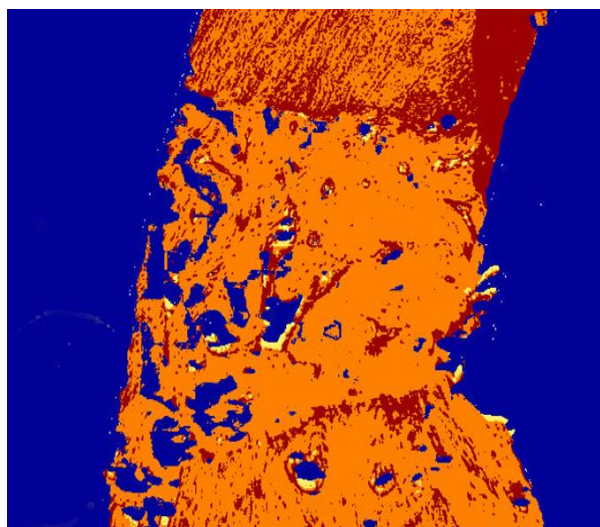
Comparative statistical analysis results between control and experimental group for 2 weeks and 4 weeks: The statistics for the new bone formation were estimated in all groups in different duration of 2 and 4 weeks. In the comparison of new bone formation between the control group and treated group by unpaired T-Test, the mean value of new bone showed highly significant differences in all groups with different duration (control Mean±SD at 2wks  $0.56 \pm 0.27$ , at 4wks  $1.66 \pm 0.76$ ) (Calcitonin+TCP Mean±SD at 2wks  $2.78 \pm 0.63$  at 4wks  $5.2 \pm 1.41$ )

Immunohistochemical study: Expression of Anti-Osteocalcin antibody Two weeks after surgical operation A-Control group: Bone section at the fracture site after two weeks for the control group showed positive immunostaining reactivity in the bone marrow stromal cells and wide distribution in the connective tissue. (Figure 5).

Treated group with Salmon Calcitonin and  $\beta$ -Tricalcium phosphate: showed positive reactivity in the newly formed trabecular bone matrix with active osteocytes cells and osteoblasts cells (Figure 6).




**Figure (5):** Markup image analyzed by Aperio imagescope software; Brown color=strong positive, Orange color=positive, Yellow color=weak positive, Blue color=negative.




**Figure (6):** Markup image analyzed by Aperio imagescope software; Brown color=strong positive, Orange color=positive, Yellow color=week positive, Blue color=negative.

Expression of Anti-Osteocalcin antibody Four weeks after surgical operation: Control group: Immunohistochemical expression of anti-osteocalcin antibody at the fracture site after four weeks for the control group showed positive reactivity in the bone marrow stromal cells, osteocytes cells, osteoblasts cells with wide formation of trabecular bone. (Figure 7).

Treated group with Salmon Calcitonin and  $\beta$ -Tricalcium phosphate: Immunohistochemical expression of anti-osteocalcin antibody for the bone section at the fracture site after two weeks for the Treated group with Salmon Calcitonin and  $\beta$ -Tricalcium phosphate showed positive reactivity in the newly formed bone with active osteocytes cells and osteoblasts cells (Figure 8).



**Figure (7):**.B- Markup image analyzed by Aperio imagescope software; Brown color=strong positive, Orange color=positive, Yellow color=week positive, Blue color=negative.



**Figure (8):**.B- Markup image analyzed by Aperio imagescope software; Brown color=strong positive, Orange color=positive, Yellow color=week positive, Blue color=negative.

Expression of Anti-Osteocalcin between control and experimental groups in 2 weeks duration: The expression of anti-osteocalcin antibody in control group (2 weeks) with a mean value  $0.27 \pm 0.06$  and treated group with  $\beta$ -tricalcium phosphate with a mean value  $0.43 \pm 0.04$  and treated group with  $\beta$ -tricalcium phosphate with salmon calcitonin mean value  $0.5 \pm 0.05$  showed a significant increase in mean value, T-test is positive.

Expression of Anti-Osteocalcin between control and experimental groups in 4 weeks duration: The expression of anti-osteocalcin antibody in the control group (4 weeks) with a mean value  $0.29 \pm 0.06$  and treated group with beta-tricalcium phosphate with a mean value  $0.5 \pm 0.05$  and with treated group with beta-tricalcium phosphate with salmon calcitonin mean value  $0.73 \pm 0.07$  showed a significant increase in mean value, T-test is positive.

## Discussion

The present study evaluated early bone fractured healing in the Rabbit femur model after the application of bone grafting material (Beta-Tricalcium phosphate), and Calcium Metabolism Modifiers miacalcic (Salmon Calcitonin) drugs. Experimental study for histological features and changes in the new bone formation area demonstrates that the treated group at the fractured femur bone site showed a remarkable difference in the treated group with  $\beta$ -TCP and Salmon calcitonin compared to control group; this result is confirmed by Vieira et al., in 2008 who found that the histological sections of the control group show the osseous defect filled with bony connective tissue and with non-

connected, immature bone trabeculae. In the present study, the maturity of newly deposited bone was obtained for each interval for a treated group with salmon calcitonin and beta-tricalcium phosphate. a treated group with daily intramuscular injection of salmon calcitonin as a minimum dose (2 IU/kg) with bone grafting materials showed a faster healing process through newly formed bone spicules that were greater than that seen in the control group and a treated group with only beta-tricalcium phosphate during each interval 2 weeks and 4 weeks period. Disagree with J. D. Almeida et al., in 2007 said that salmon calcitonin stimulates bone formation in rats, the experimental group received 2 IU/kg of diluted synthetic salmon calcitonin intramuscularly three times a week, showed a lower level of bone formation at almost all times points than the control group, but no difference between groups was observed 28 days after surgery. In this study, the animals of the treated group with salmon calcitonin in combined with beta-tricalcium phosphate showed early bone formation registered at two weeks duration intervals with a higher level of bone formation compared to the control group. Comparative histomorphometrically analysis between control and treated groups. The histomorphometry analysis of this study showed the bone formation area was different in each group, with better results highly significant for a treated group with salmon calcitonin and beta-tricalcium phosphate during each interval. The evidence virtuous effect of systemic administration of synthetic salmon calcitonin on male rats. Some experimental studies have shown a favorable effect of salmon calcitonin on surgical defect healing in ovariectomized or non-ovariectomized rats, without the application of bone graft beta-tricalcium phosphate materials as mentioned by (Arisawa et al., 2000).

The Immunohistochemical evaluation of Anti-Osteocalcin Antibody expression in new bone formation early osteogenesis process was promoted, so as the number of osteoblasts in the periphery of trabecular bone augmented, led to an illustrated increase in the expression of osteocalcin with the early bone formation which become at peak levels at 2 weeks, was revealed in the treated group with tricalcium phosphate and salmon calcitonin highly significant than the treated group with tri-calcium phosphate alone, and control group during 2<sup>nd</sup> weeks and 4<sup>th</sup> weeks of the treated period which showed a significant increase in osteocalcin expression, that agree with (Groeneveld. and Burger. 2000) said that bone mineralization process takes place from day 7 to day 14 . the expression of osteocalcin reached its peak in the second week and decreased gradually during the next observed weeks (Itagaki et al., 2008) this previous study disagreement with our result which showed that significant osteocalcin expression in the treated

group with tricalcium phosphate with increase significant rate in the treated group with tricalcium phosphate and salmon calcitonin at 4 weeks period. this previous study disagreement with our result which showed that significant osteocalcin expression in the treated group with tricalcium phosphate with increase significant rate in the treated group with tricalcium phosphate and salmon calcitonin at 4 weeks period.

## Conclusions and Recommendation:

$\beta$ -tricalcium phosphate and calcitonin were more effective in the acceleration of the early bone healing process and enhancement of bone regeneration. calcitonin induces bone formation by increasing the osteogenesis and early appearance of trabecular bone. Systematically daily administration of Salmon calcitonin with 2 IU/kg was sufficient to induce the healing bone process and has no serious adverse effects or toxicity. The combination used of  $\beta$ -tricalcium phosphate and calcitonin revealed a novel result in the acceleration of bone healing in the rabbit.

We recommended that extended the number of treated groups from one week to six weeks. The radiologic appearance of bone formation during the bone fracture healing period is used to judge the competence of the fundamental biologic process and predict the likely time for healing. Serum osteocalcin measurement for correlation with phases of early bone formation. Study the effect of using calcitonin on musculoskeletal trauma in humans. ultrastructure of study for early bone formation using an electron microscope.

## References

- Arisawa EAL, Rocha RF, Carvalho YR, Moraes E, and Almeida JD., 2000. Influência da calcitonina na reparação óssea de tíbias de ratas ovariectomizadas. *Pós-Grad Rev Fac Odontol São José dos Campos*.
- Aulakh TS and Tanaka T. 2009 Long-term clinical outcomes following the use of synthetic hydroxyapatite and bone graft in impaction in revision hip arthroplasty. *Biomaterials*.
- Costoff A. 2008 "Sect. 5, Ch. 6: Anatomy, Structure, and Synthesis of Calcitonin (CT)". *Endocrinology: hormonal control of calcium and phosphate*.
- Groeneveld EJJ, and Burger EH., 2000. Bone morphogenetic proteins in human bone regeneration. *Eur J Endocrinol*;142: 9-21.
- Hironori Sugimoto, Yusuke Inagaki, Akira Furukawa, Tsutomu Kira, Sachiko Kawasaki, Yoshinobu Uchihara, Manabu Akahane & Yasuhito Tanaka 2021.  $\beta$ -Tricalcium phosphate and their properties.
- Itagaki T, Honma T, and Takahashi I., 2008. Quantitative analysis and localization of mRNA transcripts of type I collagen, osteocalcin, MMP2, MMP8, and MMP13 during bone healing in a rat calvarial experimental defect model. *AnatRec*.

- J. D. Almeida, E. A. L. Arisawa, R. F. da Rocha, and Y. R. Carvalho., 2007. Effect of calcitonin on bone regeneration in male rats: a histomorphometric analysis. *Int. J. Oral Maxillofac.*
- Lee K. C., Park M. O., Na D. H., Youn Y. S., Lee S. D., Yoo S. D., Lee H. S., DeLuca P. P. 2003. Intranasal delivery of PEGylated salmon calcitonins: hypocalcemic effects in rats. *Calcif Tissue.*
- Matthew B. McLaughlin; Ishwarlal Jialal. 2022, California. 18 July. Northstate University, VA Medical center, Mather, CA. Calcitonin study Treasure Island (FL); StatPearls Publishing.
- Moore KL, Agur AM. 2009 *Clinically Oriented Anatomy*, 6th ed, Williams & Wilkins, Baltimore.
- Naot D. and Cornish J. 2008. The role of peptides and receptors of the calcitonin family in the regulation of bone metabolism. *Bone.*
- Qian Z, Li H, Yang H, Yang Q, Lu Z, Wang L, Chen Y, Li X. 2021. "Osteocalcin attenuates oligodendrocyte differentiation and myelination via GPR37 signaling in the mouse brain". *Science Advances.*
- Sekiguchi, Toshio; Kuwasako, Kenji; Ogasawara, Michio; Takahashi, Hiroki; Matsubara, Shin; Osugi, Tomohiro; Muramatsu, Ikunobu; Sasayama, Yuichi; Suzuki, Nobuo; Satake, Honoo 2016. Salmon calcitonin interview.
- Seokhwan Yun, Dami Choi, Dong-Jin Choi, Songwan Jin, Won-Soo Yun, Jung-Bo Huh, and Jin-Hyung Shim. 2021, Bone Fracture-Treatment Method: Fixing 3D-Printed Polycaprolactone Scaffolds with Hydrogel Type Bone-Derived Extracellular Matrix and  $\beta$ -Tricalcium Phosphate as an Osteogenic Promoter. 23. Aug.
- Theofilos Karachalios, George P Lyritis, Dionyssis G Giannarakos, George Papanicolaou and Kostas Sotopoulos. 2009, Calcitonin effects on rabbit bone 24 Nov.
- Vieira EMM; Camila Satie Ferreira Ueno; Vivian Neves Valva; Maria das Graças Vilela Goulart; Terezinha de Oliveira Nogueira; and Mônica Fernandes Gomes., 2008. Bone regeneration in cranioplasty and clinical complications in rabbits with alloxan-induced diabetes. *Braz.*