

“CLINICODERMOSCOPIC EVALUATION OF STRESS-RELATED HAIR DISORDERS IN ADOLESCENTS IN COMPETITIVE ACADEMIC ENVIRONMENTS”

Dr. Ajay Patwardhan

Professor, Department of Pediatrics,
Venkateshwara Institute of Medical Sciences, Gajraula, Uttar Pradesh, India

Dr. Ruchi Patwardhan

Professor and Head of Department, Department of Dermatology, Venereology and Leprosy,
Venkateshwara Institute of Medical Sciences, Gajraula, Uttar Pradesh, India

Dr. Yogita Yadav

PG JR-3, Department of Dermatology, Venereology and Leprosy,
Venkateshwara Institute of Medical Sciences, Gajraula, Uttar Pradesh, India

Corresponding Author

Dr. Manika Kohli

PG JR-1, Department of Pediatrics,
Venkateshwara Institute of Medical Sciences, Gajraula, Uttar Pradesh, India
Email: manikakhl0@gmail.com

ABSTRACT

Background

Adolescence represents a vulnerable developmental phase during which academic competition, psychosocial stress, and lifestyle alterations may precipitate various stress-related hair disorders. Increasing educational pressure, prolonged screen exposure, irregular sleep patterns, and psychological distress among students have contributed to a growing burden of hair-related complaints in dermatology practice. Clinicodermoscopy has emerged as a valuable non-invasive diagnostic modality for evaluating hair and scalp disorders with enhanced diagnostic precision.

Objective: *To evaluate the clinicodermoscopic patterns of stress-related hair disorders among adolescents exposed to competitive academic environments and to analyze the association between psychological stress and clinical hair manifestations.*

Methods: *A hospital-based cross-sectional observational study was conducted in the Departments of Dermatology and Pediatrics at Venkateshwara Institute of Medical Sciences, Gajraula, Uttar Pradesh, over a period of 12 months. A total of 150 adolescents aged 12–19 years presenting with hair-related complaints and exposed to competitive academic environments were enrolled. Detailed clinical history, stress-related factors, scalp examination, and dermoscopic assessment were performed. Psychological stress was assessed using the Perceived Stress Scale (PSS-10). Dermoscopic findings were documented using polarized dermoscopy. Statistical analysis was performed using SPSS version 26.0.*

Results: *The mean age of participants was 16.1 ± 2.2 years, with female predominance (60%). Telogen effluvium was the most common diagnosis (42.7%), followed by trichotillomania (18.0%), alopecia areata (16.7%), seborrheic dermatitis-associated hair fall (14.0%), and traction alopecia (8.6%). High stress scores were significantly associated with diffuse hair shedding, broken hairs, black dots, yellow dots, hair diameter diversity, and perifollicular scaling ($p < 0.05$). Female adolescents demonstrated significantly greater psychosocial distress compared to males. Sleep deprivation and prolonged study duration were strongly associated with severity of hair loss.*

Conclusion: *Stress-related hair disorders are increasingly prevalent among adolescents in competitive academic settings. Clinicodermoscopy serves as an effective non-invasive diagnostic tool for early recognition and differentiation of stress-induced hair disorders. Psychological counseling, stress management strategies, and multidisciplinary intervention are essential components of holistic adolescent healthcare.*

Keywords : *Clinicodermoscopy; Adolescent Hair Disorders; Telogen Effluvium; Trichotillomania; Alopecia Areata; Psychological Stress; Dermoscopy*

INTRODUCTION

Adolescence is a critical transitional period characterized by rapid physical, hormonal, emotional, and psychosocial changes. During this developmental phase, individuals are particularly susceptible to psychological stressors arising from academic expectations, peer pressure, family demands, competitive examinations, social media exposure, and concerns related to self-image and identity. In recent years, the increasing intensity of competitive academic environments has emerged as a major contributor to stress-related health problems among adolescents. Among these manifestations, stress-induced hair disorders are increasingly being recognized as an important yet underappreciated clinical entity. (1)

Hair plays a significant role in body image, social interaction, self-esteem, and psychological well-being, particularly during adolescence when appearance-related concerns become highly prominent. Hair loss or scalp disorders during this sensitive period can lead to emotional distress, social withdrawal, anxiety, depression, and reduced quality of life. Conversely, psychological stress itself can precipitate or aggravate various hair disorders, thereby creating a vicious cycle between emotional stress and dermatological disease. (2)

Stress-related hair disorders encompass a broad spectrum of conditions including telogen effluvium, trichotillomania, alopecia areata, traction alopecia, diffuse hair shedding, seborrheic dermatitis-associated hair fall, and psychogenic scalp disorders. Among these, telogen effluvium is one of the most common causes of diffuse non-scarring alopecia associated with physical or emotional stress. It results from premature transition of hair follicles from the anagen phase into the telogen phase, leading to excessive hair shedding several weeks after exposure to stressors. (3)

Alopecia areata is another important autoimmune hair disorder frequently associated with psychological stress. Stress-mediated neuroimmunological mechanisms involving cytokine

dysregulation, altered neuropeptide release, and immune dysfunction have been implicated in disease initiation and progression. Similarly, trichotillomania, characterized by recurrent compulsive hair pulling, is strongly associated with anxiety disorders, obsessive-compulsive spectrum disorders, emotional trauma, and academic stress. (4)

The pathophysiological relationship between stress and hair disorders is complex and multifactorial. Activation of the hypothalamic-pituitary-adrenal axis during stress leads to increased cortisol secretion, neurogenic inflammation, perifollicular immune dysregulation, and alterations in the hair growth cycle. Stress-induced oxidative damage and microvascular changes further contribute to follicular dysfunction and impaired hair growth. Adolescents exposed to prolonged academic stress often exhibit associated sleep deprivation, nutritional imbalance, irregular dietary habits, and sedentary lifestyle patterns, all of which may aggravate hair loss. (5)

Competitive academic environments, particularly among students preparing for board examinations, medical entrance tests, engineering entrance examinations, and other high-pressure educational systems, have become increasingly stressful in modern society. Studies from India and other developing countries have demonstrated high prevalence of anxiety, depression, sleep disorders, and psychosomatic symptoms among adolescents facing academic competition. However, limited literature exists evaluating the dermatological consequences of chronic academic stress, particularly hair disorders among adolescents. (6)

Traditional clinical examination of hair disorders may sometimes be insufficient for accurate diagnosis, especially in early or overlapping conditions. In this context, dermoscopy has emerged as a valuable, non-invasive diagnostic tool for the assessment of scalp and hair disorders. Hair dermoscopy, also known as trichoscopy, allows magnified visualization of hair shafts, follicular openings, vascular structures, perifollicular changes, and scalp morphology that are not appreciable to the naked eye. It significantly improves diagnostic accuracy and reduces the need for invasive scalp biopsy procedures. (7)

Characteristic dermoscopic findings have been described in various stress-related hair disorders. Telogen effluvium typically demonstrates hair shaft diameter diversity and numerous empty follicles. Alopecia areata may reveal yellow dots, black dots, exclamation mark hairs, cadaverized hairs, and short vellus hairs. Trichotillomania often shows broken hairs of varying lengths, flame hairs, coiled hairs, tulip hairs, and perifollicular hemorrhage. Seborrheic dermatitis demonstrates diffuse scaling and arborizing vessels. Recognition of these patterns facilitates early diagnosis and appropriate management. (8)

Despite increasing awareness regarding adolescent mental health and psychosomatic disorders, stress-related hair disorders remain relatively underdiagnosed in routine clinical practice. Many adolescents present late due to embarrassment, social stigma, or lack of awareness. Furthermore, psychological stress assessment is not routinely incorporated into dermatological evaluation. Early recognition of stress-induced hair disorders is essential because timely intervention may prevent progression, improve psychosocial outcomes, and reduce long-term emotional morbidity.

The present study was therefore undertaken to evaluate the clinicodermoscopic patterns of stress-related hair disorders among adolescents exposed to competitive academic environments and to analyze the relationship between psychological stress and clinical hair manifestations using standardized clinical and dermoscopic assessment tools.

OBJECTIVES

Primary Objective

To evaluate the clinicodermoscopic patterns of stress-related hair disorders among adolescents in competitive academic environments.

Secondary Objectives

1. To assess the prevalence of various stress-related hair disorders among adolescents.
2. To evaluate the association between psychological stress levels and severity of hair disorders.
3. To identify characteristic dermoscopic findings associated with stress-induced hair disorders.
4. To analyze lifestyle and academic factors contributing to hair disorders among adolescents.

MATERIALS AND METHODS

This hospital-based cross-sectional observational study was conducted jointly in the Department of Dermatology, Venereology and Leprosy and the Department of Pediatrics at Venkateshwara Institute of Medical Sciences, Gajraula, Uttar Pradesh, over a period of 12 months from January 2025 to December 2025. The study included adolescents presenting with complaints related to hair loss, hair thinning, scalp disorders, or stress-associated hair abnormalities in the outpatient departments.

A total of 150 adolescents aged between 12 and 19 years were enrolled in the study after obtaining informed consent from parents or guardians and assent from the participants wherever appropriate. Adolescents studying in competitive academic settings including board examination preparation, coaching institutes, entrance examination preparation programs, and high-performance educational environments were included in the study. Participants presenting with clinically evident hair disorders associated with recent or ongoing psychological stress were considered eligible.

Patients with congenital hair disorders, scarring alopecia, active systemic infections, endocrine disorders such as hypothyroidism, severe nutritional deficiencies, chemotherapy-induced alopecia, autoimmune connective tissue disorders, or those receiving medications known to cause hair loss were excluded from the study. Adolescents with severe psychiatric illness or inability to cooperate with dermoscopic examination were also excluded.

Detailed demographic information including age, gender, educational status, duration of academic study hours, sleep duration, dietary habits, family history, and duration of hair complaints was recorded using a structured case record form. A comprehensive dermatological examination of the scalp and hair was performed in all participants under standardized clinical conditions.

Psychological stress levels were assessed using the validated Perceived Stress Scale-10 (PSS-10), which measures perceived stress during the previous month. Scores were categorized as low stress (0–13), moderate stress (14–26), and high perceived stress (27–40). Clinical severity of hair disorders was assessed based on hair density reduction, extent of scalp involvement, and symptom duration.

Clinicodermoscopic examination was performed using a polarized handheld dermoscope with 10× magnification attached to a digital imaging system. Multiple scalp areas including frontal, parietal, temporal, vertex, and occipital regions were examined systematically. Dermoscopic findings such as yellow dots, black dots, broken hairs, exclamation mark hairs, coiled hairs, vellus hairs, perifollicular scaling, hair shaft diameter diversity, flame hairs, comma hairs, empty follicles, and scalp vascular changes were documented photographically.

The final diagnosis was established based on combined clinical and dermoscopic findings. Cases showing diffuse hair shedding with positive hair pull test and absence of inflammatory or scarring features were diagnosed as telogen effluvium. Presence of broken hairs of varying lengths, coiled hairs, flame hairs, and irregular patches suggested trichotillomania. Alopecia areata was diagnosed in cases showing yellow dots, exclamation mark hairs, black dots, and circumscribed alopecic patches.

Ethical clearance for the study was obtained from the Institutional Ethics Committee of Venkateshwara Institute of Medical Sciences prior to commencement of the study. Confidentiality and anonymity of all participants were strictly maintained throughout the research process.

All collected data were entered into Microsoft Excel and analyzed using Statistical Package for Social Sciences (SPSS) software version 26.0. Quantitative variables were expressed as mean ± standard deviation, while qualitative variables were represented as frequencies and percentages. Chi-square test, Student's t-test, ANOVA, and Pearson correlation analysis were applied wherever appropriate. A p-value less than 0.05 was considered statistically significant.

RESULTS

A total of 150 adolescents with stress-related hair disorders were included in the study. The mean age of participants was 16.1 ± 2.2 years. The majority of participants belonged to the age group of 15–17 years (46.7%), followed by 12–14 years (32.0%) and 18–19 years (21.3%). Female participants constituted 60.0% of the study population, while males accounted for 40.0%.

The mean duration of hair-related complaints was 7.4 ± 3.2 months. Nearly 68% of participants reported study duration exceeding 8 hours daily, and 58% reported sleep duration of less than 6 hours per day during examination periods.

Telogen effluvium emerged as the most common diagnosis, affecting 64 (42.7%) participants, followed by trichotillomania in 27 (18.0%), alopecia areata in 25 (16.7%), seborrheic dermatitis-associated hair fall in 21 (14.0%), and traction alopecia in 13 (8.6%) adolescents.

Table 1: Demographic Characteristics of Study Participants (n = 150)

Variable	Frequency (n)	Percentage (%)
Age Group (Years)		
12–14	48	32.0
15–17	70	46.7
18–19	32	21.3
Gender		
Male	60	40.0
Female	90	60.0
Average Daily Study Duration		
<6 hours	24	16.0
6–8 hours	54	36.0
>8 hours	72	48.0
Average Sleep Duration		
<6 hours	87	58.0
6–8 hours	51	34.0
>8 hours	12	8.0

Interpretation

Most adolescents belonged to highly competitive academic settings characterized by prolonged study hours and reduced sleep duration.

Table 2: Distribution of Stress-Related Hair Disorders

Hair Disorder	Frequency (n)	Percentage (%)
Telogen Effluvium	64	42.7
Trichotillomania	27	18.0
Alopecia Areata	25	16.7
Seborrheic Dermatitis-associated Hair Fall	21	14.0
Traction Alopecia	13	8.6

Interpretation

Telogen effluvium was the predominant stress-related hair disorder observed among adolescents.

The mean Perceived Stress Scale (PSS-10) score among participants was 24.8 ± 5.6 . High perceived stress levels were observed in 62 (41.3%) adolescents, while 71 (47.3%) demonstrated moderate stress levels.

A significant positive correlation was observed between stress scores and severity of hair shedding ($r = 0.62$, $p < 0.001$). Adolescents with higher stress scores demonstrated greater hair density reduction, increased scalp symptoms, and more extensive dermoscopic abnormalities.

Table 3: Association Between Stress Levels and Hair Disorders

Stress Category	Number of Participants	Predominant Hair Disorder	Mean Score	Severity
Low Stress	17	Mild Telogen Effluvium	3.1 ± 1.2	
Moderate Stress	71	Telogen Effluvium	5.8 ± 1.9	
High Stress	62	Trichotillomania / Alopecia Areata	8.2 ± 2.4	

Interpretation

Increasing psychological stress was associated with greater severity and complexity of hair disorders.

Dermoscopic examination revealed characteristic findings corresponding to different hair disorders. Hair shaft diameter diversity and empty follicles were predominantly observed in telogen effluvium, while trichotillomania demonstrated broken hairs of varying lengths, flame hairs, coiled hairs, and perifollicular hemorrhage. Alopecia areata showed yellow dots, black dots, exclamation mark hairs, and short vellus hairs.

Table 4: Dermoscopic Findings Observed Among Participants

Dermoscopic Finding	Frequency (n)	Percentage (%)
Hair Shaft Diameter Diversity	82	54.7
Empty Follicles	74	49.3
Broken Hairs	52	34.7
Yellow Dots	39	26.0
Black Dots	31	20.7
Exclamation Mark Hairs	24	16.0

Coiled Hairs	28	18.7
Perifollicular Scaling	43	28.7
Flame Hairs	17	11.3
Vellus Hairs	35	23.3

Interpretation

Hair shaft diameter diversity and empty follicles were the most common dermoscopic findings associated with stress-induced diffuse hair loss.

Female adolescents demonstrated significantly higher emotional distress scores and greater cosmetic concern compared to males ($p = 0.02$). Sleep deprivation, irregular meals, caffeine overconsumption, and prolonged digital screen exposure were significantly associated with worsening hair symptoms.

Participants preparing for board examinations and competitive entrance examinations showed significantly higher stress scores compared to school-going adolescents not enrolled in coaching programs ($p < 0.001$).

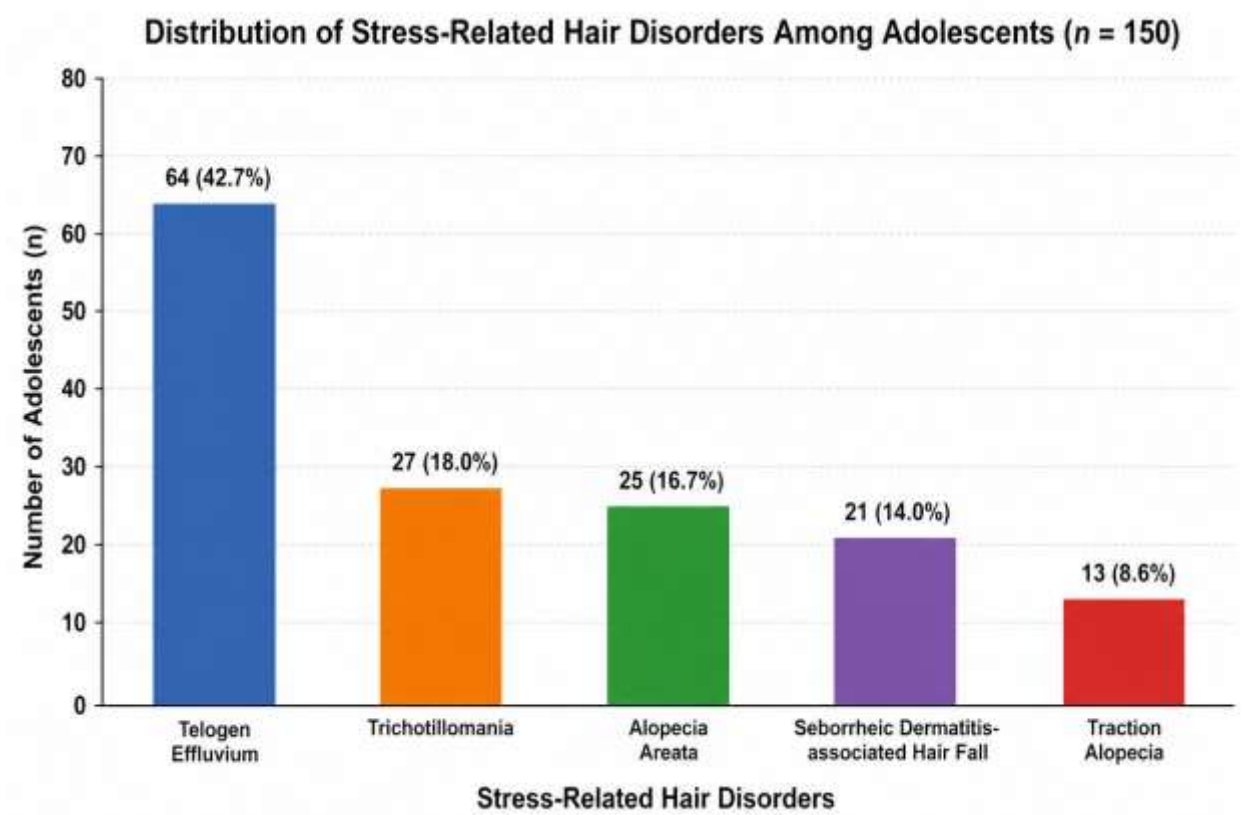


Figure 1: Bar graph showing distribution of various stress-related hair disorders among adolescents.

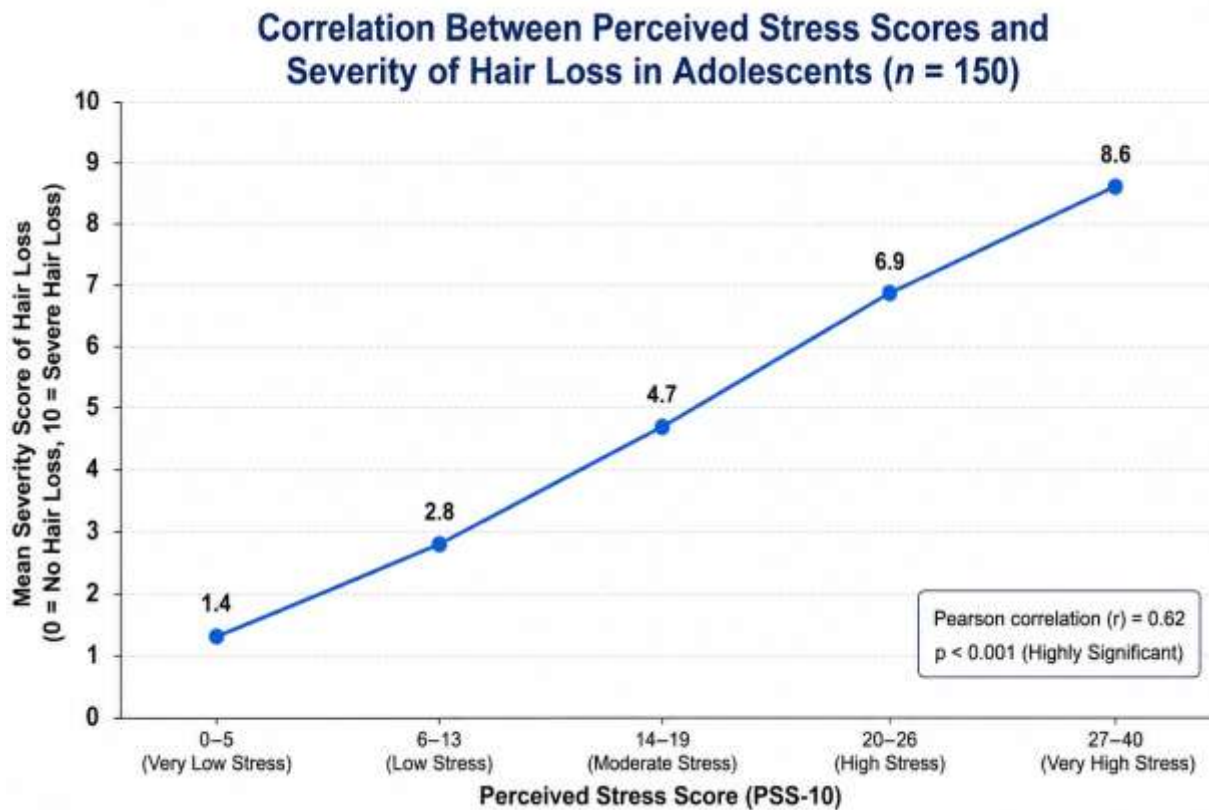


Figure 2: Line graph illustrating positive correlation between perceived stress scores and severity of hair loss.

DISCUSSION

The present study evaluated the clinicodermoscopic characteristics of stress-related hair disorders among adolescents exposed to competitive academic environments. The findings demonstrated a substantial burden of psychological stress-associated hair disorders among adolescents, particularly among students facing prolonged academic pressure and sleep deprivation.

Telogen effluvium emerged as the most common diagnosis in the present study, accounting for 42.7% of cases. This observation is consistent with previous studies demonstrating emotional stress as a major precipitating factor for diffuse non-scarring alopecia among adolescents and young adults. Stress-induced alterations in the hair growth cycle are believed to precipitate premature follicular transition from anagen to telogen phase, resulting in excessive hair shedding. Chronic activation of the hypothalamic-pituitary-adrenal axis and increased cortisol secretion contribute significantly to this pathological process. (9)

Children and adolescents with stress-related hair disorders frequently experience significant psychosocial morbidity, including low self-esteem, anxiety, embarrassment, and social withdrawal. In the present study, female adolescents demonstrated comparatively higher emotional distress scores than male participants. Similar observations have been reported in previous studies where cosmetic concerns, social expectations, and body image issues contributed to greater psychological burden among adolescent girls. Hair loss during adolescence may significantly affect confidence and interpersonal relationships, particularly in educational and peer-interactive settings. (10)

Alopecia areata constituted 16.7% of cases in the present study. Several studies have established a strong association between psychological stress and alopecia areata through neuroimmunological pathways involving cytokine dysregulation, perifollicular inflammation, and autoimmune activation. Dermoscopic findings including yellow dots, black dots, exclamation mark hairs, and short vellus hairs observed in the present study were consistent with classical trichoscopic features reported in earlier literature. (11)

Trichotillomania was observed in 18.0% of adolescents and was particularly common among students with high stress scores and prolonged study duration. Trichotillomania is considered a psychodermatological disorder characterized by compulsive hair pulling behavior triggered by emotional stress, anxiety, frustration, or obsessive tendencies. Dermoscopic examination in these patients demonstrated broken hairs of varying lengths, flame hairs, coiled hairs, and perifollicular hemorrhage, which are considered characteristic diagnostic findings. Similar dermoscopic observations have been described by Rakowska et al. and other trichoscopy-based studies. (12)

One of the important observations of the present study was the significant association between reduced sleep duration and severity of hair disorders. More than half of the participants reported sleeping less than six hours daily, particularly during examination periods. Sleep deprivation is known to increase oxidative stress, hormonal imbalance, inflammatory cytokine release, and cortisol secretion, all of which negatively affect follicular cycling and scalp health. Previous studies have also demonstrated that chronic sleep deficiency contributes to diffuse hair shedding and worsening of inflammatory scalp disorders. (13)

The role of competitive academic environments as a contributor to adolescent stress has become increasingly important in recent years. Students preparing for medical entrance examinations, engineering entrance tests, and board examinations often experience prolonged psychological stress due to performance pressure, parental expectations, academic competition, and fear of

failure. In the present study, adolescents enrolled in coaching institutes and high-intensity educational programs demonstrated significantly higher stress scores and more severe hair disorders compared to other participants. These findings highlight the growing psychosomatic impact of modern educational systems on adolescent health.

Clinicodermoscopy proved to be an extremely valuable diagnostic modality in the present study. Traditional clinical examination alone may occasionally fail to differentiate early hair disorders with overlapping presentations. Dermoscopy allows detailed visualization of follicular and shaft abnormalities that aid in accurate diagnosis and early intervention. Hair shaft diameter diversity and empty follicles were the most common findings in telogen effluvium, whereas yellow dots and black dots predominated in alopecia areata. Trichotillomania demonstrated highly characteristic broken hairs, coiled hairs, and flame hairs. These findings are comparable with previous trichoscopic studies conducted in pediatric and adolescent populations. (14)

The present study also observed significant association between lifestyle factors and severity of hair disorders. Irregular meals, nutritional imbalance, excessive caffeine intake, reduced physical activity, and prolonged digital screen exposure were commonly reported among participants. These factors may aggravate oxidative stress and metabolic imbalance, further contributing to hair follicle dysfunction. The modern sedentary lifestyle associated with prolonged academic preparation may therefore indirectly worsen stress-related dermatological conditions.

From a clinical perspective, the findings of the present study emphasize the importance of adopting a multidisciplinary approach in adolescents presenting with hair disorders. Management should not only focus on pharmacological therapy but also include stress reduction techniques, counseling, sleep hygiene improvement, nutritional optimization, and behavioral interventions. Early recognition of psychosocial triggers can significantly improve therapeutic outcomes and prevent chronic progression.

The present study has several strengths. It incorporated both clinical and dermoscopic evaluation, utilized a validated psychological stress assessment scale, and evaluated adolescents from competitive academic environments, an area with limited available literature. Furthermore, the study contributes important regional data from North India regarding psychodermatological disorders among adolescents.

However, certain limitations must be acknowledged. Being a single-center cross-sectional study, long-term follow-up and causal relationship assessment were not possible. The study relied partially on self-reported stress-related information, which may introduce reporting bias. Additionally, biochemical stress markers such as serum cortisol levels were not evaluated.

Despite these limitations, the findings clearly demonstrate the growing prevalence of stress-related hair disorders among adolescents exposed to academic pressure. Early clinicodermoscopic evaluation combined with psychological assessment may facilitate prompt diagnosis, targeted intervention, and improved quality of life among affected individuals.

CONCLUSION

Stress-related hair disorders constitute an increasingly important clinical and psychosocial problem among adolescents exposed to competitive academic environments. Telogen effluvium, trichotillomania, and alopecia areata were the most commonly observed conditions in the present study, with significant association between psychological stress levels and severity of hair manifestations.

Clinicodermoscopy proved to be a highly effective non-invasive diagnostic tool for early identification and differentiation of various stress-related hair disorders. Characteristic dermoscopic findings including hair shaft diameter diversity, broken hairs, yellow dots, black dots, flame hairs, and perifollicular changes significantly enhanced diagnostic accuracy.

Academic stress, sleep deprivation, prolonged study duration, and unhealthy lifestyle patterns emerged as important contributing factors. Early psychological counseling, stress management strategies, lifestyle modification, and multidisciplinary care are essential to improve both dermatological and psychosocial outcomes among adolescents.

Routine incorporation of stress assessment and clinicodermoscopic evaluation in adolescent dermatology practice may facilitate holistic patient-centered management and prevent long-term emotional morbidity.

REFERENCES

1. Patel V, Flisher AJ, Hetrick S, McGorry P. Mental health of young people: a global public health challenge. *Lancet*. 2007;369(9569):1302-1313.
2. Hunt N, McHale S. The psychological impact of alopecia. *BMJ*. 2005;331(7522):951-953.
3. Malkud S. Telogen effluvium: a review. *J Clin Diagn Res*. 2015;9(9):WE01-WE03.
4. Gupta MA, Gupta AK. Psychodermatology: an update. *J Am Acad Dermatol*. 2013;69(1):1-13.
5. Arck PC, Paus R. From the brain-skin connection: the neuroendocrine-immune misalliance of stress and itch. *Neuroimmunomodulation*. 2006;13(5-6):347-356.
6. Deb S, Strodl E, Sun H. Academic stress, parental pressure, anxiety and mental health among Indian high school students. *Int J Psychol Behav Sci*. 2015;5(1):26-34.
7. Rudnicka L, Olszewska M, Rakowska A. Trichoscopy: how it may help the clinician. *Dermatol Clin*. 2013;31(1):29-41.
8. Rakowska A, Slowinska M, Kowalska-Oledzka E, Rudnicka L. Dermoscopy in female androgenic alopecia: method standardization and diagnostic criteria. *Int J Trichology*. 2009;1(2):123-130.
9. Harrison S, Sinclair R. Telogen effluvium. *Clin Exp Dermatol*. 2002;27(5):389-395.
10. Cash TF. The psychosocial consequences of androgenetic alopecia: a review of the research literature. *Br J Dermatol*. 2001;141(3):398-405.
11. Alkhalifah A, Alsantali A, Wang E, McElwee KJ, Shapiro J. Alopecia areata update. *J Am Acad Dermatol*. 2010;62(2):177-188.

12. Rakowska A, Olszewska M, Rudnicka L. Trichoscopy of trichotillomania. *J Dermatol Case Rep.* 2008;2(2):14-20.
13. Hirotsu C, Tufik S, Andersen ML. Interactions between sleep, stress, and metabolism: from physiological to pathological conditions. *Sleep Sci.* 2015;8(3):143-152.
14. Rudnicka L, Rakowska A, Olszewska M. Hair shaft disorders in trichoscopy. *Dermatol Clin.* 2018;36(4):421-431.
15. Sehgal VN, Srivastava G. Trichotillomania: psychiatric and dermatologic perspectives. *Skinmed.* 2006;5(5):235-240.
16. Messenger AG, Sinclair R. Follicular disorders. In: Burns T, Breathnach S, Cox N, Griffiths C, editors. *Rook's Textbook of Dermatology.* 9th ed. Oxford: Wiley-Blackwell; 2016. p. 89.1-89.75.
17. Olsen EA. Female pattern hair loss. *J Am Acad Dermatol.* 2001;45(3):S70-S80.
18. Paus R, Cotsarelis G. The biology of hair follicles. *N Engl J Med.* 1999;341(7):491-497.
19. Finlay AY, Khan GK. Dermatology Life Quality Index (DLQI): practical aspects. *Clin Exp Dermatol.* 1994;19(3):210-216.
20. Tosti A, Torres F, Misciali C. Dermoscopy in hair disorders. *J Egypt Women Dermatol Soc.* 2009;6(2):69-74.