

## **Orthodontic correction of severe crowding ,increased overjet and deepbite in Angle’s Class I malocclusion: A case report**

**Ayesha Naaz, Karuna Singh Sawhny , Sujit Panda, Bilal Ahmad Bhat**

Rama Dental College, Hospital and Research Centre,  
Rama University, Kanpur, U.P India.  
ayeshanaaz12081994@gmail.com

### **ABSTRACT –**

This case report describes the treatment of 15 years old female patient, who presented with severe crowding, bimaxillary protrusion, proclined maxillary and mandibular anteriors, with increased overjet, deepbite and Class I molar relationship. Orthodontic Treatment was started using fixed orthodontic appliance MBT followed by four premolar extractions (14,24,35,44) in both the arches. Molars were finished in a Class I relationship. Good intercuspation of upper and lower teeth were achieved after the treatment along with ideal overjet and overbite. case was successfully completed with proper overjet, overbite, patient attained beautiful smile with improved soft tissue profile.

**Keywords:** Class I malocclusion, proclination, crowding, premolars extraction

### **INTRODUCTION**

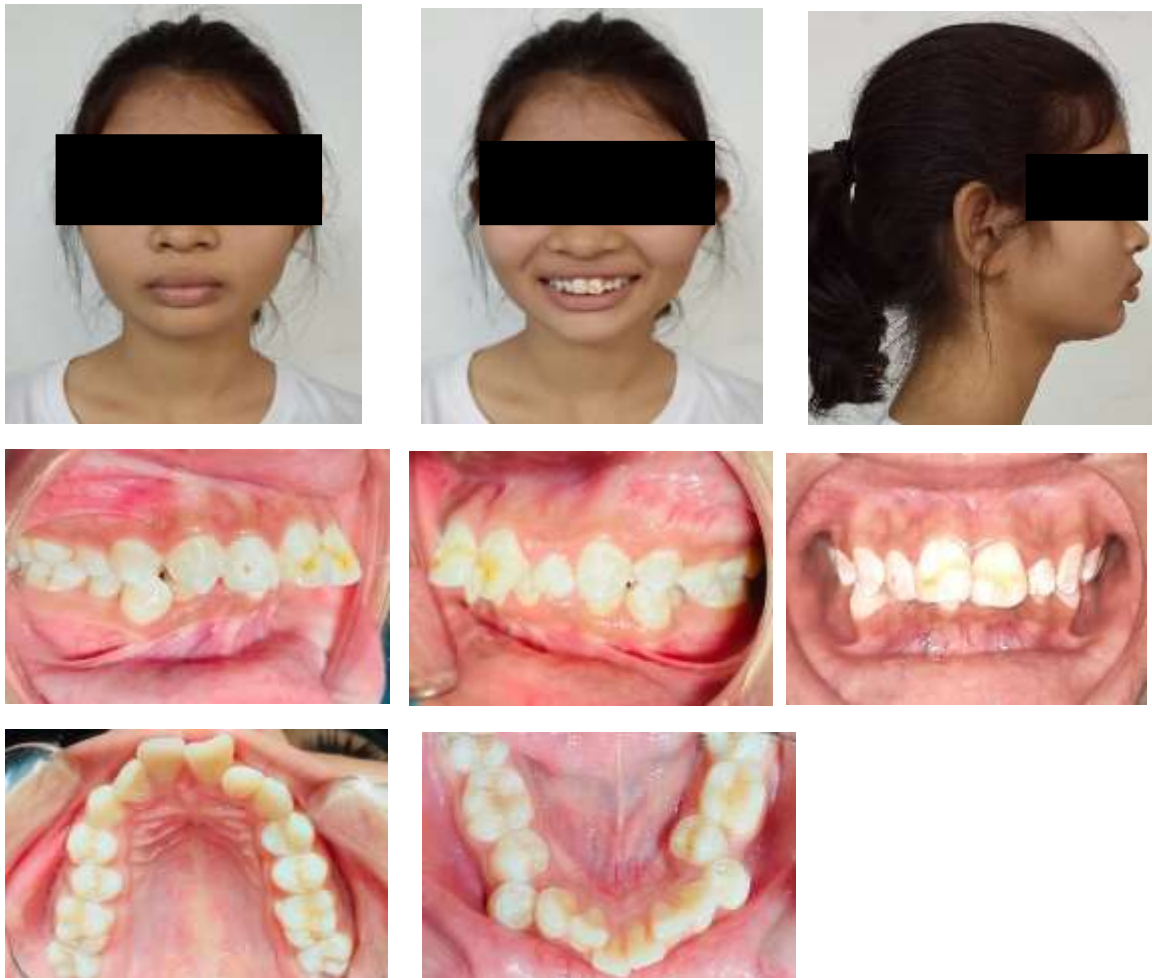An orthodontist's primary goal is to correct malocclusions. A perfectly aligned set of teeth would produce optimum facial aesthetics for each individual. There are two ways that malocclusion can occur: crowding and spacing, with crowding being the most frequent cause. Space gaining is necessary for treating a crowded arch. Two therapeutic modalities—extraction or non-extraction—have been used to accomplish this. In extraction, premolars are the most common tooth being spared in orthodontic treatment<sup>1</sup>. Premolars seem to be the ideal choice for treating crowding and anterior-posterior discrepancies because of their convenient location between the anterior and posterior segments. different premolar extraction techniques create spaces in different location of the arches. It is also possible to choose an extraction plan that eliminates premolars that are unusually big or little and add to a Bolton discrepancy. The factors that have the most bearing on the result of the procedure include the patient's age, preferences, the skill of the orthodontists, the types and degrees of malocclusion, and the treatment philosophies<sup>2</sup>. To achieve good result, it is important to decide how to manage each case of crowding. Teeth extraction in both arches<sup>3</sup> or no extraction<sup>4</sup> at all may be the solution to the issue. The length of the procedure is also influenced by the extent of malocclusion and the quantity of teeth extracted<sup>5</sup>.

### **CASE REPORT**

A 15 year old female patient came to the Department of Orthodontics and Dentofacial Orthopedics with the chief complaint of the forwardly placed upper teeth and crowding in lower teeth. she doesn't have any kind of medical history. Extraoral examination revealed convex profile with posterior divergence, competent lips, and acute nasolabial angle.

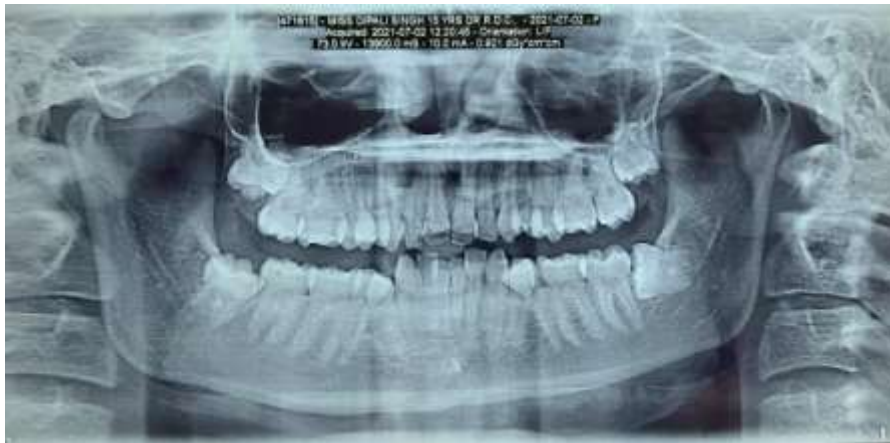**CLINICAL EXAMINATION**

The patient was mesomorphic and had a normal gait and erect posture. The face was euryprosopic with competent lips. Profile was convex with an average clinical FMA and normal chin. Clinical examination showed proclination and crowding of upper and lower incisors. The patient has a bimaxillary protrusion with Angle's class I molar relationship bilaterally and Rickett's class II (end on) canine relationship bilaterally with increased overjet (7 mm) and overbite (4 mm) with coincided midline (figure 1). The examination further revealed that 44 was buccally placed and 35 was lingually placed. Impacted 18,28,38,48, radiolucency present in 11, 21 (figure 2). lateral cephalometric analysis revealed a skeletal class I relationship with a horizontal growth pattern (figure 3).

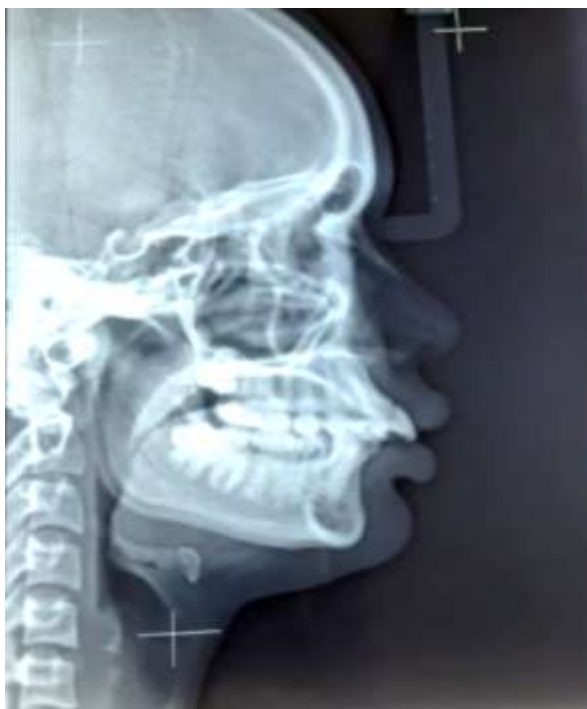

(figure 1 )

**Ayesha Naaz:** Orthodontic correction of severe crowding ,increased overjet and deepbite in Angle’s Class I malocclusion: A case report



(figure 2)



(figure 3 )

TABLE 1

Measurement	ideal values	Pretreatment values
SNA	82 deg	85 deg
SNB	79 deg	82 deg
ANB	3 deg	3 deg
FMA	24 deg	17 deg
IMPA	95 deg	111.5 deg
Jaraback’s Ratio	65 %	76.23 %
Lower 1 to N-B (mm)	4 mm	6 mm
Upper 1 to N-A (mm)	4 mm	11.5 mm
Interincisal angle	131 deg	103 deg
Nasolabial angle	90-110 deg	78 deg
Angle of convexity	1.5±5.8	6 deg

### **TREATMENT PLANNING –**

According to the information collected from the clinical examination and the diagnostic records, it was planned to relieve the maxillary and mandibular crowding and reduced the overjet and overbite with fixed appliance

The problem list is as follows:

1. Proclination of upper arch
2. Increased overjet
3. Severe crowding in upper and lower arch
4. Deepbite

Treatment objectives –

1. To align the teeth
2. To establish balanced occlusal relationship bilaterally
3. To maintain correct overbite and overjet
4. To relieve crowding
5. To constitute a good aesthetic smile
6. To correct canine relationship

Treatment planning was suggested as follows –

1. Extraction of 14,24,35,44
2. Alignment of upper and lower teeth with preadjusted edgewise appliance (MBT, 0.022 slots)
3. Retention with the upper and lower removable Begg's retainers.

### **TREATMENT PROGRESS**

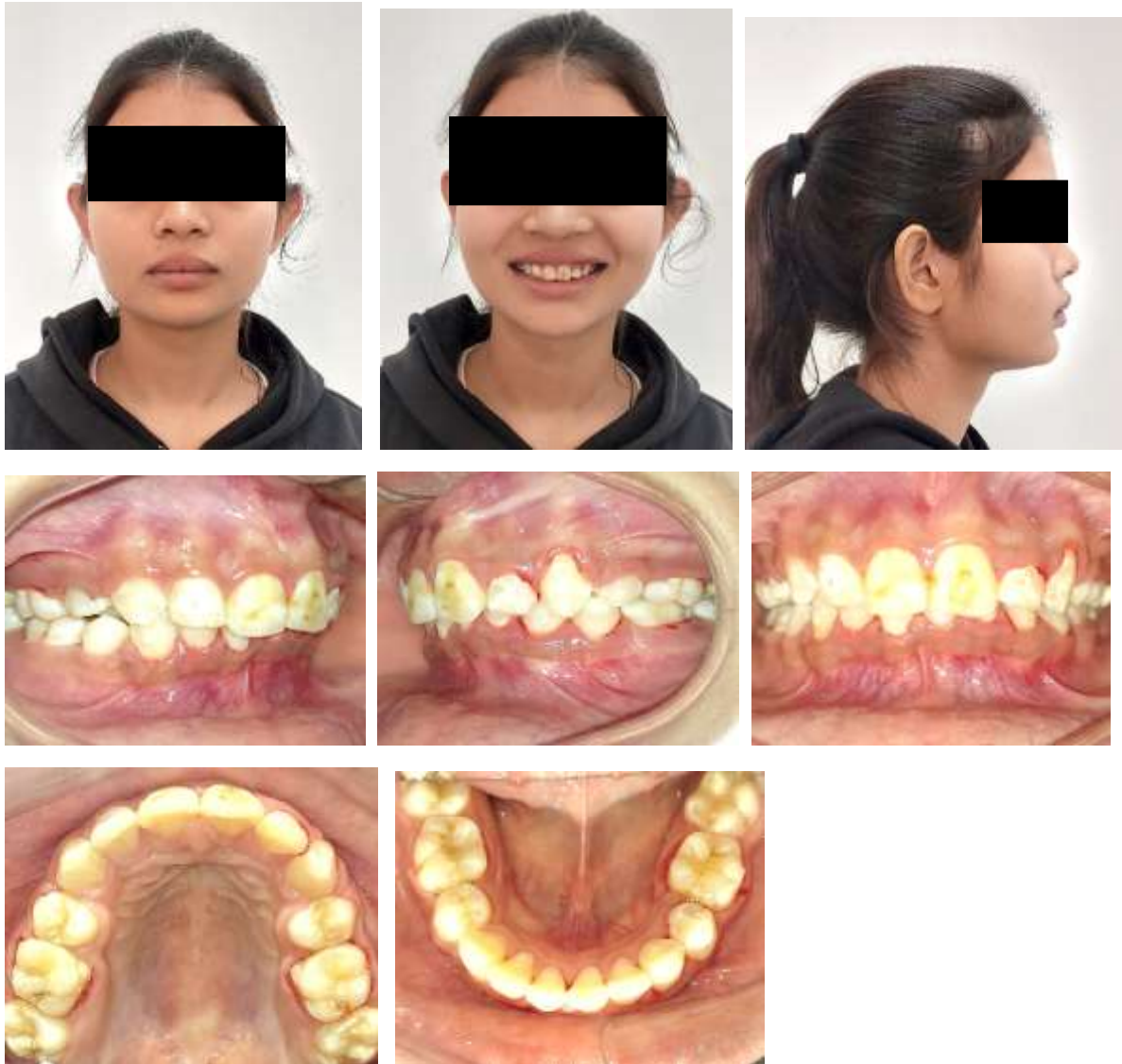Treatment was started by bonding the fixed appliance using 0.022 slots preadjusted edgewise brackets, MBT prescription with banding of 36,37,46,47. Anchorage control is very important for the successful orthodontic treatment. so the anchorage control was achieved by cementing nance on the maxillary arch for the prevention of mesial movement of maxillary molars in the extraction spaces. Levelling and alignment was done using 0.012 NiTi, 0.014NiTi, 0.016 NiTi, 0.016 SS, 0.018 SS, 0.017x0.025 NiTi, 0.017x0.025 SS,0.019x0.025 NiTi, 0.019 x 0.025 SS archwire . the patient was examined and called every 4 weeks for monitoring.

The upper and lower anteriors were then consolidated and canine retraction was started. After the canine retraction .0.018 RCS wire was given in lower arch followed by 17 x 25 RCS. Assymetrical T LOOP was placed for the upper anterior retraction. After the space closure, 0.014 NiTi (settling wire) was ligated. once the occlusion was settled, debonding of the appliance was done. retention was achieved with Begg's retainers in both arches.

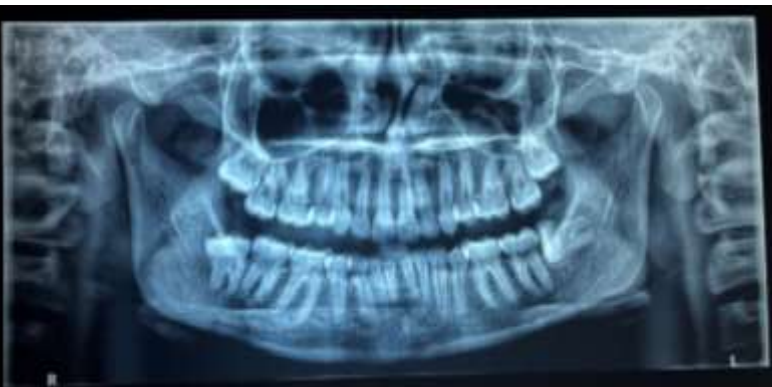### **RESULT**

Total time taken for the completion of the orthodontic treatment was 18 months. Angle's Class I molar relationship was maintained. After the treatment, a proper overjet and overbite were achieved, crowding was relieved in both the arches. Good intercuspation of the maxillary and mandibular teeth was attained.

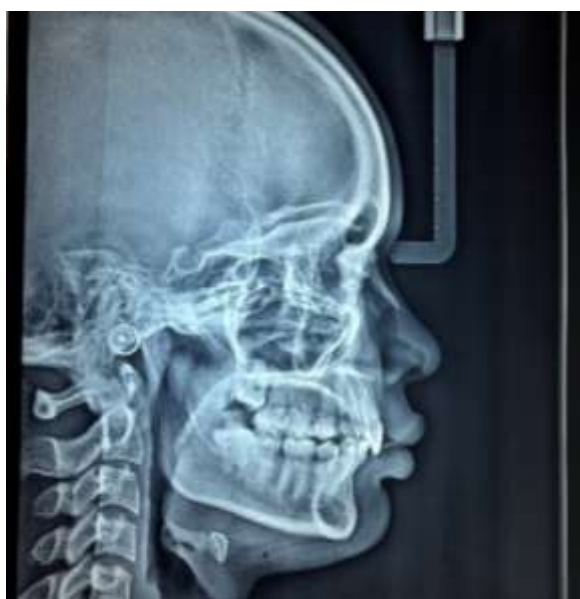**Ayesha Naaz:** Orthodontic correction of severe crowding ,increased overjet and deepbite in Angle's Class I malocclusion: A case report



(figure 4)



(figure 5)



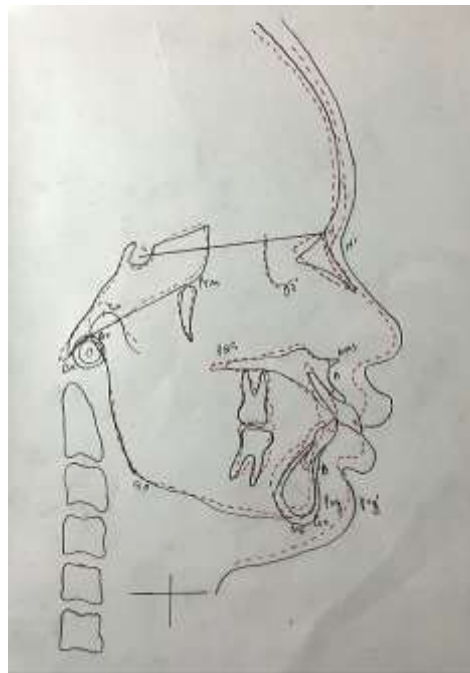
(figure 6)

TABLE 2

Measurement	ideal values	Pretreatment values	Posttreatment values
SNA	82 deg	85 deg	83 deg
SNB	79 deg	82 deg	80 deg
ANB	3 deg	3 deg	3 deg

**Ayesha Naaz:** Orthodontic correction of severe crowding ,increased overjet and deepbite in Angle’s Class I malocclusion: A case report

FMA	24 deg	18 deg	20 deg
IMPA	95 deg	111.5 deg	106 deg
Jaraback’s Ratio	65 %	76.23 %	75 %
Lower 1 to N-B (mm)	4 mm	6 mm	4 mm
Upper 1 to N-A (mm)	4 mm	11.5 mm	4 mm
Interincisal angle	131 deg	103 deg	129 deg
Nasolabial angle	90-110 deg	78 deg	96 deg
Angle of convexity	1.5+5.8deg	6 deg	5 deg



(figure 7 )

**DISCUSSION**

Selecting an extraction pattern needs thorough analysis and is a skill. Based on the degree of malocclusion, different indications apply for first and second premolar extraction<sup>6</sup>. Orthodontic treatment has been aiming to achieve specific aims systematically and scientifically since ancient times. One of the primary objectives of orthodontic treatment is to preserve the stability of the occlusion following orthodontic treatment. To determine the stability of the occlusion, numerous orthodontic research have been conducted<sup>7,8</sup>. Treatment stability is dependent on several factors, including the kind of malocclusion, patient participation, growth, and flexibility of the hard and soft tissues<sup>9</sup>.

In this case, orthodontic diagnosis and treatment planning were determined by aesthetic considerations. Our attention was directed towards correcting the patient's upper and lower arch crowding and proclination in relation to the soft tissue profile. When patients come with a crowded arch, there is debate over the most effective treatment strategy (extraction versus non-extraction) to achieve long-term stability. Premolar extraction is a recognised procedure to correct the crowded arch. However, teeth may revert to their pre-treatment position even with retraction during

extraction therapy. Today, non-extraction orthodontic treatment approaches are preferred over extraction because of the increased emphasis on the aesthetics of soft tissue profiles and growth changes<sup>10</sup>.

Fixed appliance therapy can not only correct the dental irregularities but also dramatically change and enhance the facial profile. The field of facial aesthetics has been more and more in demand in the current century. Even the smallest misalignment of the teeth can now be corrected with orthodontic treatment, giving the patient a better smile and facial profile. In addition to correction of tooth irregularities, fixed appliance therapy can dramatically change and enhance facial attractiveness. It can be difficult to treat a teenage patient's maxillary and mandibular crowding when four premolars need to be extracted. The best approach to guarantee consistent outcomes with little to no side effects is to develop a well-thought-out, personalised treatment plan that is carried out using good biomechanical principles and suitable management of orthodontic mechanics.

### **CONCLUSION**

This case report illustrates how a case with crowding can be managed with Extraction of 4 premolars by means of appropriate use of conventional MBT prescription along with efficient conservation of anchorage at the same time. The planned goals set in the pre-treatment plan were successfully attained. Good intercuspation of the upper and lower teeth was achieved with a Class I molar, incisor and canine relationship. Treatment of the crowded, proclined and forwardly placed upper and lower anterior teeth included the retraction of maxillary and mandibular incisors with a resultant decrease in soft tissue procumbency and facial convexity. The upper and lower teeth were found to be esthetically satisfactory in the line of occlusion. smile and profile of the patient was improved. The correction of the malocclusion was achieved, with a significant improvement in the patient aesthetics and self-esteem. The patient was very happy with the outcome of the treatment.

### **References**

1. Proffit W, Forty year review of extraction frequency at a university orthodontic clinic, *Angle Orthod* 1994; 407– 14.
2. Yu HS, Baik HS, Sung SJ, Kim KD, Cho YS. Threedimensional finite-element analysis of maxillary protraction with and without rapid palatal expansion. *Eur J Orthod.* 2007;29(2):118–25.
3. Yamamoto T, Torii M, Yashiro K, Takada K. Treatment of Angle Class III malocclusion with tooth-size discrepancy caused by the large upper and lower first premolar teeth. *Orthod Wave.* 2008;67(2):81-6. 4.
4. Cai B, Zhao X-G, Xiang L-S. Orthodontic decompensation and correction of skeletal Class III malocclusion with gradual dentoalveolar remodeling in a growing patient. *Am J Orthod Dent Orthop.* 2014;145(3):367-80. 5.
5. Vig KWL, Weyant R, Vayda D, O'Brien KD, Bennett E. Orthodontic process and outcome: efficacy studies—strategies for developing process and outcome measures: a new era in orthodontics. *Clin Orthod Res.* 1998;1:147-55.



**Ayesha Naaz:** Orthodontic correction of severe crowding ,increased overjet and deepbite in Angle's Class I malocclusion: A case report

6. Mascarenhas R, Majithia P, Parveen S. Second premolar extraction: Not always a second choice. *Contemp Clin Dent.* 2015 Jan-Mar;6(1):119-23. doi: 10.4103/0976-237X.149307. PMID: 25684927; PMCID: PMC4319330.
7. Little RM, Riedel RA, Årtun J. An evaluation of changes in mandibular anterior alignment from 10 to 20years postretention.*Am J Orthod Dentofacial Orthop.* 1988;93:423-28.8.
8. Fidler BC, Årtun J, Joondeph DR, Little RM. Long-term stability of Angle Class II Division 1 malocclusions with successful occlusal results at end of active treatment. *Am J Orthod Dentofacial Orthop.* 1995;107:276-85
9. Al Yami AE, Kuijpers-Jagtman AM, Van't Hof MA. Stability of orthodontic treatment outcome:follow-up until 10 years postretention. *Am J Orthod Dentofac Orthop.* 1999;115:300-04
10. Erdinc AE, Nanda RS, Işıksal E. Relapse of anterior crowding in patients treated with extraction and nonextraction of premolars. *Am J Orthod Dentofac Orthop.*2006;129(6):775-84