

MANAGING ENDODONTIC PRACTICES USING CONE-BEAM COMPUTED TOMOGRAPHY: A REVIEW

Saurabh Sharma, Asheesh Sawhny, Mukta Bansal, Richa Singh, Saurav Paul, Pankaj Priyadarshi

Rama Dental College Hospital & Research Centre, Rama University, Mandhana, Kanpur, Uttar Pradesh-India 209217

ABSTRACT

Traditionally, conventional periapical radiology formed the backbone of endodontic for diagnosis, treatment planning, and management. One of the major associated gripes being the technique created two-dimensional images of three-dimensional (3D) structures, suffered magnification, superimposition, and distortion, leading to compromised diagnostic information. The need to analyze the area of interesting all the possible planes led to the introduction of cone-beam computed tomography (CBCT), a novel modality specifically designed to produce precise, undistorted 3D reconstructed images of the maxillofacial skeleton. CBCT is increasingly being embraced by various fields in dentistry, remarkably in endodontic practice. A systematic literature-based and book-based review was conducted using the keywords “CBCT in endodontics” and “endodontic applications of CBCT.” This article hereby discusses the prospects of CBCT in endodontics with an emphasis on its application in diagnosis and management along with treatment outcome assessment.

INTRODUCTION

Conventional radiology is the fundamental tool of endodontic practice and needed for the successful management of any endodontic crisis. It comprises the basis of all the stages of endodontic treatment starting from diagnosis, intraoperative procedure assessment, treatment planning, and evaluation of treatment outcome.[1] Although two-dimensional (2D) imaging is still the most routinely followed modality in practice, it comes with the precinct of being a planar imaging technique. Hence, arose the need for a three-dimensional (3D) imaging system which could give a better assessment of the area of interest^{2,3} Cone-beam computed tomography (CBCT) is the current modality of choice with emphatic results, especially in endodontic imaging. The aim of this paper is to review the pertinent literature focusing on applications of CBCT In contemporary endodontic practice, also highlighting the merits and demerits of CBCT.

ENDODONTIC COMPLICATIONS

During routine endodontic procedures, clinicians encounter various intraoperative challenges, including missed canals, complex root canal anatomy, fractured instruments, asymptomatic non-healing periapical and resorptive lesions, perforations, root and cortical bone fractures, apicomarginal communication, maxillary sinus involvement, sinus membrane thickening, and

inadequate root canal obturation systems. Postoperatively, persistent pain and swelling around the treated tooth and surrounding soft tissue areas are commonly observed. To date, conventional periapical radiography has been the primary tool for assessing pre-, intra-, and post-operative stages of treatment⁴. Despite its significant contributions, this technique has inherent limitations that are discussed herein.

Periapical radiography cannot fully assess the three-dimensional spatial relationship between tooth roots and surrounding anatomical structures like the inferior alveolar canal, mental foramen, and maxillary sinus^{6,7}. Additionally, it may not adequately reveal anatomical complexities, the extent of resorptive lesions, or iatrogenic errors. Evaluating root angulation and cortical plate thickness for presurgical planning is challenging due to the lack of third-dimensional diagnostic information. Even with multiple radiographs taken at different angles, complete detection of all relevant structures or pathologies is not guaranteed^{8,9}.

Among the two prevalent techniques used in conventional and digital intraoral imaging, namely the bisecting angle and paralleling technique, the latter is considered to be more accurate. In this, the receptor is placed parallel to the object (tooth) and X-ray is directed perpendicular to the arrangement. Although distortion gets minimized, parallelism is governed by local anatomy.¹³ Paralleling technique works well with flat 2D structures, but it is imperfect for the multirooted teeth.^[9] Furthermore, magnification happens to be inherent to the central projection principle used in intraoral radiography¹³.

Anatomical structures such as the incisive foramen, maxillary sinus, and zygomatic buttress can obscure the region of interest (ROI) in 2D images, making it challenging to interpret them accurately due to superimposition. The complexity of these anatomical features leads to reduced contrast in the ROI¹⁴. Periapical lesions confined to cancellous bone are difficult to visualize on plain radiographs, leading to underestimation of their size and extent^{15,16}. Factors affecting the visualization of periapical lesions and resorptive defects include overlying anatomy, cancellous bone thickness, cortical plate integrity, trabecular patterns, bone marrow spaces, and the relationship of root apices with the cortical plate. Considering these factors, it can be concluded that periapical radiography offers suboptimal diagnostic information^{17,18}.

In endodontics, radiographs used for pretreatment, posttreatment, and follow-up stages should adhere to standards regarding density, contrast, and radiation geometry. Additionally, the dimension of time is crucial, requiring series of radiographs over time to be standardized in these three aspects. Poorly standardized radiographs can result in inaccurate assessments of healing progression. Achieving this level of standardization is challenging with conventional planar imaging methods, necessitating the introduction of new techniques in dentistry. Limited cone-beam computed tomography (CBCT) has emerged as a preferred option, rapidly becoming the standard of care in endodontic and dental imaging¹⁹.

INTRODUCTION TO CONE-BEAM COMPUTED TOMOGRAPHY

One of the earliest 3D imaging modalities introduced in medical imaging was the computed tomography (CT) system. However, it came with limitations such as high cost, lengthy scanning procedures, and high radiation exposure for patients, as each image slice required separate scanning and reconstruction²⁰. These drawbacks led to the development of cone-beam computed tomography (CBCT) as a novel alternative. The first CBCT machine was

initially designed for angiography in 1982 by Richard Robb at the Mayo Clinic²¹. Over the following two decades, the technology underwent refinement, leading to the development of CBCT units specifically for dentomaxillofacial imaging around 1988. By the early 1990s, manufacturers introduced improved office-based CBCT scanners that retained the advantages of CT scanning while minimizing the disadvantages. CBCT is a fairly recent modality in which a pyramidal or cone-shaped X-ray beam is focused at the center of the ROI onto a detector on the opposite side [Figure 1]. The X-ray source and detector rotate and multiple sequential planar projections of the field of view (FOV) are acquired in a complete or partial arc. This 2D data are then converted with the help of algorithms into a 3D volume by a computer. CBCT aids in rapid acquisition of data with a smaller radiation exposure, and it is less expensive than CT. The volume data obtained in CBCT scans are in the form of isotropic voxels which are more precise than CT machines^{22,23}

APPLICATIONS OF CONE-BEAM COMPUTED TOMOGRAPHY IN ENDODONTICS

Assessment of root canal morphology and its variations

is important for the success of endodontic diagnosis and treatment. Periapical radiographs may reveal only up to 50% information about all the canals within the root, especially in the buccolingual plane. Such missed canals are responsible for reinfection and failure of the endodontic treatment. Most commonly missed canal causing reinfection and necessitating retreatment is the second mesiobuccal canal (MB2) present in maxillary first molars. The prevalence of MB2 canal can vary from 69 to 93%. CBCT can help in identifying MB2 canal with much more precision as compared to a conventional radiograph^{24,25} CBCT imaging can also be used to detect additional distolingual canals, “C”-shaped canal, and in assessment of canal curvature. It has been shown that CBCT reports a higher incidence of distolingual canal (33%) as compared to conventional radiography (21%)^{26,27} Matherne et al. compared different techniques and established the supremacy of CBCT in detecting the number of root canals over charged couple device detectors and photostimulable phosphor plate digital radiography.[28] CBCT scans have also proved to be useful in diagnosis and treatment planning of anatomic variations of the teeth such as dens invaginatus, dilacerated teeth, talon’s cusp, and fused roots as it can provide precise 3D information about the anatomy without any geometric distortion^{29,30}

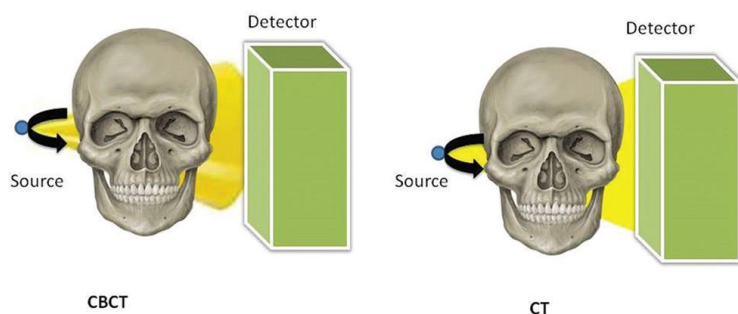


Figure 1: Comparison of the geometric configuration of incident X-ray beam projection and detector for cone-beam computed tomography and multidetector computed tomography

Detection of periapical pathosis

Routinely used periapical radiographs often fail to completely reveal the true nature and extent of progression of a periapical lesion. The lesions can be detected only when the buccal and lingual cortical involvement is present producing a distinct bone loss (30–50%) and an area of rarefaction^{31,32} Further, the details may get obscured by the presence of anatomical structures such as zygomatic arch or maxillary sinus and any radiolucent periapical lesions in these areas might go unnoticed³³ CBCT helps overcome such limitations by providing 3D reconstructed images in the axial, sagittal, and coronal planes without the overlying anatomical noise [Figures 2 and 3]. CBCT imaging is also an accurate method for measuring the volume of artificially created bone cavities using an ex vivo model thus providing a valuable tool for monitoring the healing rate of apical periodontitis (AP) as compared to conventional radiography^{34,35} A new periapical index system (CBCT-periapical index) for the identification of AP has been proposed by Estrela et al., and they concluded that CBCT imaging detected 54.2% more AP lesions than intraoral radiography³⁷ CBCT was also useful in assessing endodontic treatment outcome (a 1-year posttreatment follow-up) (17.6%) by evaluating if any periapical radiolucency existed which was commonly undiagnosed by periapical radiographs (1.3%). This was useful for identifying cases which required retreatment³⁷.

Assessment of intraoperative iatrogenic errors

Limited field of view (FOV) cone-beam computed tomography (CBCT) scans are highly beneficial for intraoperative assessments in endodontics. They enable the detection of unexpected anatomical findings, identification of calcified and missed canals during retreatment, evaluation of root curvature before rotary instrumentation, and diagnosis of iatrogenic errors like fractured instruments, overextended obturation materials, and perforations. These assessments significantly impact the outcome of endodontic treatment^{27,28}.

Assessment of dentoalveolar trauma

Traumatized teeth pose a clinical challenge with regard to their diagnosis, treatment plan, and prognosis. Periapical radiography provides poor sensitivity in the detection of minimal tooth/root displacements and alveolar fractures mostly due to projection geometry, processing errors, and the superimposition of various anatomic structures. CBCT is the imaging modality of choice for the evaluation of facial traumas, identification, and characterization of fractures with their associated complications, degree and direction of luxation injury, and in assessment of outcome^{39,40} Root fractures, classified under dentofacial trauma, form an important endodontic concern as their correct diagnosis mandates an accurate establishment of the fracture line location which in turn will determine the therapeutic possibilities⁴¹

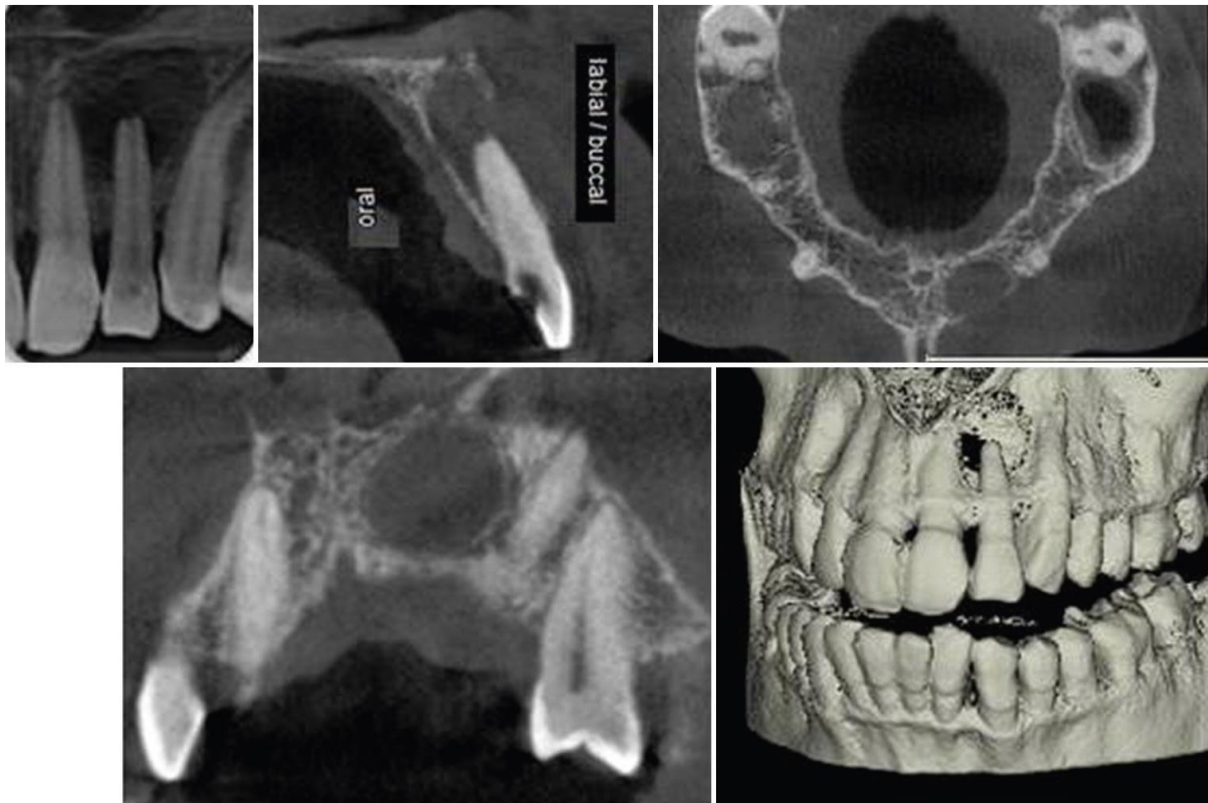


Figure 2: Periapical lesion. (a) Conventional intraoral periapical radiograph of tooth 22. (b and c) Cross-section and axial cone-beam computed tomography image of the same tooth revealing the loss of palatal cortex. (c and d) Tangential and three-dimensional reconstruction image showing the dramatic extent of lesion. (e) Three dimensional reconstruction (surface volume) depicting the loss of bone in the labial cortex and the proximity of the lesion to the floor of the nasal fossa

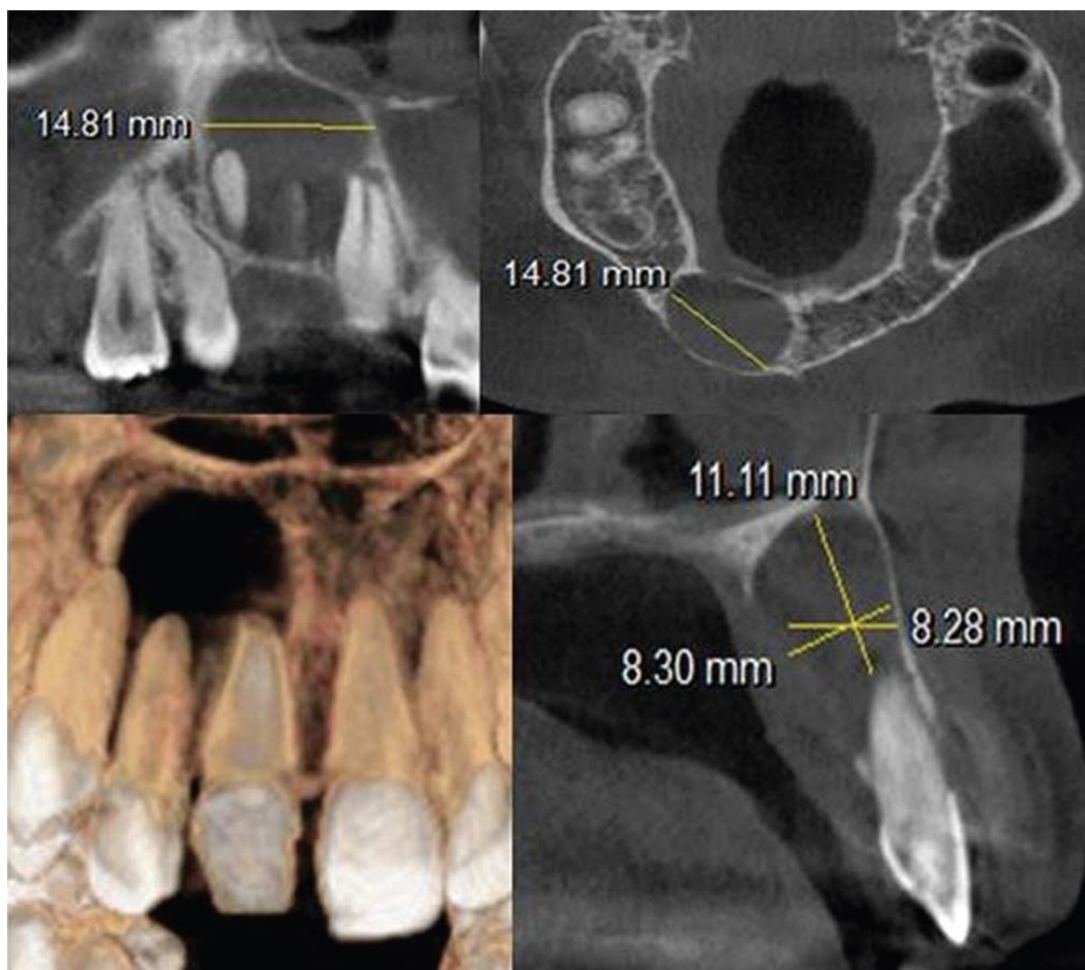


Figure 3: Various sections depicting the cystic pathology in the maxillary anterior region. The dimensions of the cyst, extent of bone loss, labial cortical plate expansion, and thinning are markedly seen hence giving a clear picture about the lesion

Vertical root fracture (VRF) is more common than the horizontal fractures and are characterized by a “through-and-through” crack connecting the pulp space and periodontal ligament. It manifests with nonspecific clinical features such as a localized deep periodontal pocket, sinus tracts, or a lateral radiolucency which complicates the diagnosis if only plain conventional radiographs are used.[42] For horizontal fracture detection, on the other hand, the vertical angle should be changed, and the central beam should be focused on the fracture plane as well as be perpendicular to the film ⁴¹.

CBCT, in this context, can provide undistorted, cross-sectional views of the fracture line without any noise and help in viewing the desired area in several orthogonal planes [Figure 4].⁴³ Hassan et al. observed that the detection of VRFs in root canal filled teeth had a higher sensitivity with CBCT in the buccolingual and mesiodistal planes (87 and 63.5%).⁴⁴ External inflammatory root resorption is also very common sequelae of luxation injury (5–18%) and avulsion cases (30%). Its diagnosis is based solely on the radiographic demonstration of the process, and CBCT alone can suffice for it ⁴⁵.

Assessment of root resorptions and perforations

Root resorption is a pathological event causing loss of dental hard tissues as a result of osteoclastic activities. Internal root resorption (IRR) within the root canal is usually asymptomatic and a serendipitous finding on routine radiographic examination, often confused and misdiagnosed with external root resorption (ERR). CBCT can be used in confirming the presence of IRR and differentiating it from ERR. The external resorption defect presents with irregular border of radiolucency and intact root canal, whereas internal resorption has clearly defined borders with no canal radiographically visible in the Defect^{45,46}. It is also useful in differentiating between invasive cervical resorption and IRR by assessing the real extent of the root defect and possible points of communication with the periodontal space⁴⁷. CBCT has the highest accuracy among the different imaging modalities in detecting perforations since there is 3D visualization of the perforation site without superimposition of neighboring structures⁴⁸.

Assessment of outcome of endodontic treatment

Three-dimensional cone-beam computed tomography (CBCT) scans play a crucial role in assessing the healing of periradicular tissues and evaluating the outcomes of endodontic treatments. Paula-Silva et al. conducted a study where they examined the periapices of 83 root canal-treated and untreated teeth using periapical radiography, CBCT, and histological analysis. The findings revealed that CBCT detected apical periodontitis (AP) in 86% of the cases. This highlighted that some cases previously deemed completely healed might exhibit a slight degree of persistent infection, underscoring the need for immediate attention⁴⁹.

Assessment of potential surgical sites

CBCT has been an extremely useful tool in the planning of surgical endodontic treatment. Rigolone et al., in 2003, studied 43 upper first molars using for microsurgery of palatal root and concluded that CBCT provided enough information for a minimally invasive microsurgical technique via the buccal side rather than the palatal

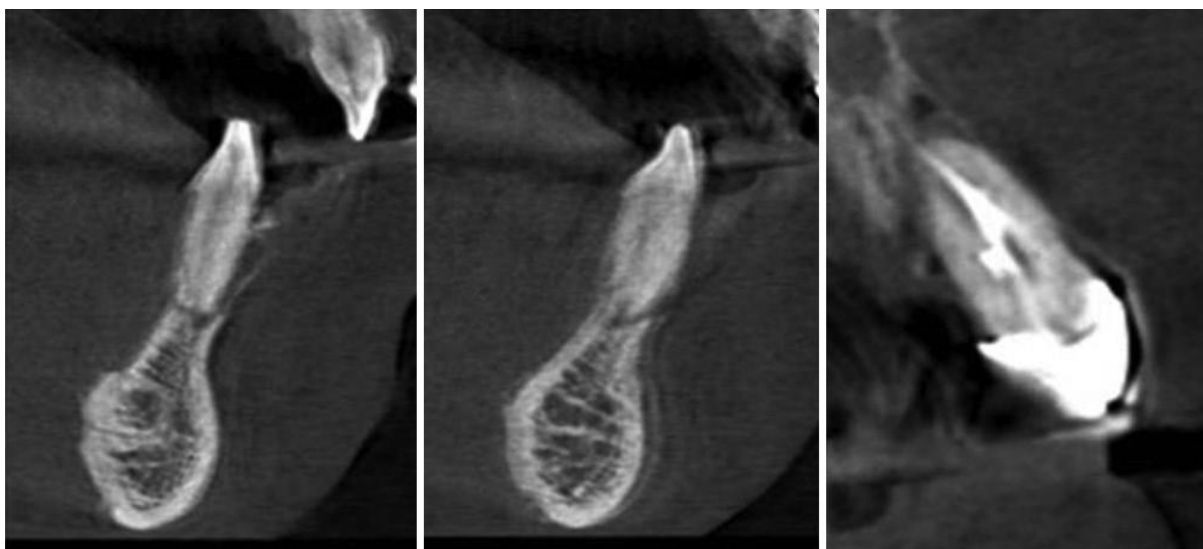


Figure 4: (a-c) Cross-sectional cone-beam computed tomography images of tooth number 31, 41, and 21, respectively, showing vertical

fracture lines

approach⁵⁰ Low et al. assessed 37 premolars and 37 molars in the maxilla, referred for apical surgery. They reported that CBCT was able to identify clearly the sinus membrane thickening, expansion of the lesion into the maxillary sinus, apicomarginal communications, pattern of root morphology, and bony topography (cancellous bone pattern and fenestrations).[33] CBCT also allows for virtual implant planning and placement of implants using the reconstructed data to fabricate a surgical guide that transfers the information to the surgical site [Figure 5]⁵¹

CONCLUSION

The success of endodontic treatment results from an accurate diagnosis and proper debridement of the root canal space. Radiographic examination continues to remain the essential part of the diagnosis and management of endodontic treatment. Although intraoral periapical radiography is an economical and accessible technique readily available to the clinicians for routine treatment procedures, CBCT imaging helps in overcoming the inherent limitations of intraoral radiography. The all-encompassing and readily available 3D data result in an accurate identification of canal morphology, early monitoring and differential diagnosis of periapical lesions, management of dentofacial trauma, analysis of resorptive lesions, and presurgical assessment, thus making CBCT the forerunner of endodontic treatment planning and outcome assessment. However, the flip side of the coin being limited availability and cost factor associated with the modality. Hence, endodontic cases should be scrutinized thoroughly, and CBCT imaging should be considered in situations where conventional radiography cannot yield adequate information for the appropriate management of endodontic problems.

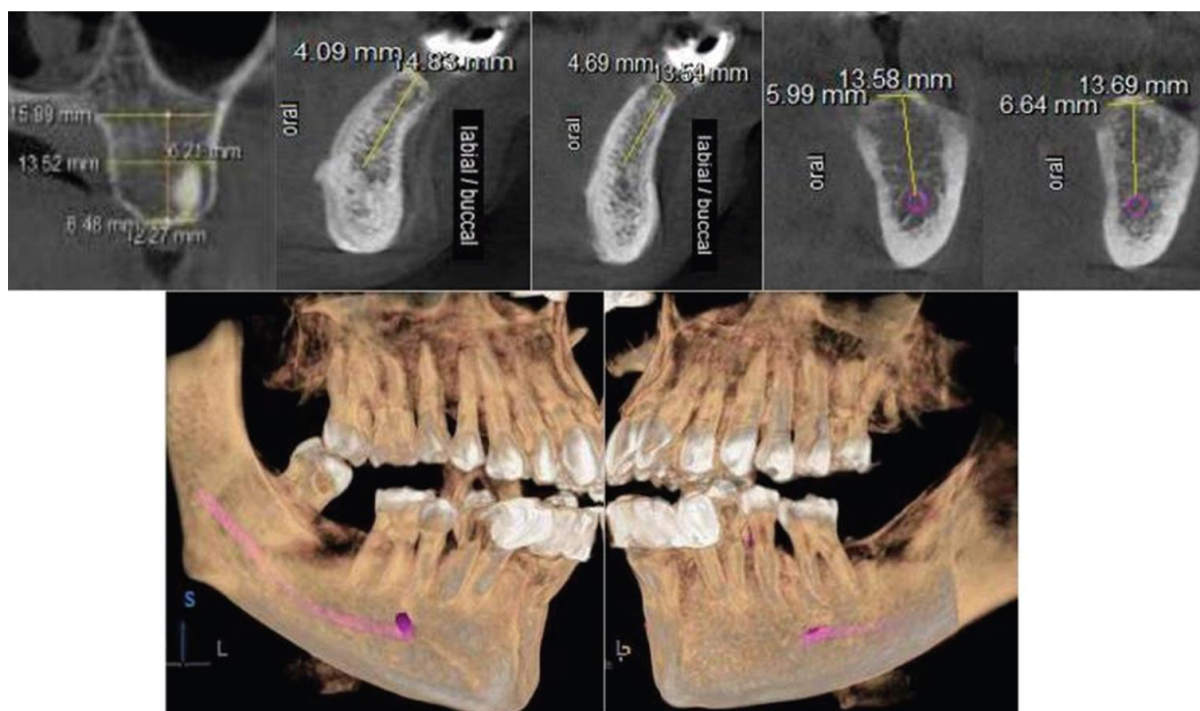


Figure 5: Cone-beam computed tomography imaging providing multiple views for the presurgical evaluation and measurement for placement of implant

REFERENCES

1. Nair MK, Nair UP. Digital and advanced imaging in endodontics: A review. *J Endod* 2007;33:1-6.
2. Langland OE, Langlais RP. Early pioneers of oral and maxillofacial radiology. *Oral Surg Oral Med Oral Pathol Oral Radiol Endod* 1995;80:496-511.
3. Danforth RA, Dus I, Mah J. 3-D volume imaging for dentistry: A new dimension. *J Calif Dent Assoc* 2003;31:817-23.
4. Patel S, Dawood A, Ford TP, Whaites E. The potential applications of cone beam computed tomography in the management of endodontic problems. *Int Endod J* 2007;40:818-30.
5. Cotti E, Campisi G. Advanced radiographic techniques for the detection of lesions in bone. *Endod Top* 2004;7:52-72.
6. Durack C, Patel S, Davies J, Wilson R, Mannocci F. Diagnostic accuracy of small volume cone beam computed tomography and intraoral periapical radiography for the detection of simulated external inflammatory root resorption. *Int Endod J* 2011;44:136-47.
7. Silva JA, de Alencar AH, da Rocha SS, Lopes LG, Estrela C. Three-dimensional image contribution for evaluation of operative procedural errors in endodontic therapy and dental implants. *Braz Dent J* 2012;23:127-34.
8. Velvart P, Hecker H, Tillinger G. Detection of the apical lesion and mandibular canal in conventional radiography and computed tomography. *Oral Surg Oral Med Oral Pathol Endod* 2001;92:682-98.
9. Whaites E. Periapical radiography. In: Whaites E, editor. *Essentials of Dental Radiology and Radiography*. 4th ed. Philadelphia, USA: Churchill Livingstone Elsevier; 2007. p. 75-100.
10. Wenzel A. A review of the dentists' use of digital radiography and caries diagnosis with digital systems. *Dentomaxillofac Surg* 2006;35:307-14.
11. Barton DJ, Clark SJ, Eleazer PD, Scheetz JP, Farman AG. Tuned aperture computed tomography versus parallel analogue and digital radiographic images in detecting second mesiobuccal canals in maxillary first molars. *Oral Surg Oral Med Oral Pathol Oral Radiol Endod* 2003;96:223-8.
12. Lofthag-Hansen S, Huuononen S, Gröndahl K, Gröndahl HG. Limited cone-beam CT and intraoral radiography for the diagnosis of periapical pathology. *Oral Surg Oral Med Oral Pathol Oral Radiol Endod* 2007;103:114-9.
13. Alothmani OS, Friedlander LT, Chandler NP. Radiographic assessment of endodontic working length. *Saudi Endod J* 2013;3:57-64.
14. Kundel HL, Revesz G. Lesion conspicuity, structured noise, and film reader error. *AJR Am J Roentgenol* 1976;126:1233-8.
15. Bender IB, Seltzer S. Roentgenographic and direct observation of experimental lesions in bone. *J Am Dent Assoc* 1961;62:152-60.
16. Schwartz SF, Foster JK. Roentgenographic interpretation of experimentally produced bony lesions: Part 1. *Oral Surg Oral Med Oral Pathol* 1971;32:606-12.
17. Andreasen JO. Experimental dental traumatology: Development of a model for external root resorption. *Endod Dent Traumatol* 1987;3:269-87.
18. Gröndahl HG, Huuononen S. Radiographic manifestations of periapical inflammatory lesions. *Endod Top* 2004;8:55-67.
19. Friedman S. Prognosis of initial endodontic therapy. *Endod Topics* 2002;2:59-98.
20. Farman AG, Levato CM, Scarfe WC. 3D X-ray: An update. *Inside Dent* 2007;3:70-4.

21. Robb RA. The dynamic spatial reconstructor: An X-ray video-fluoroscopic CT scanner for dynamic volume imaging of moving organs. *IEEE Trans Med Imaging* 1982;1:22-33.
22. Scarfe WC, Farman AG. What is cone-beam CT and how does it work? *Dent Clin North Am* 2008;52:707-30, v.
23. Hashimoto K, Kawashima S, Araki M, Iwai K, Sawada K, Akiyama Y. Comparison of image performance between cone-beam computed tomography for dental use and four-row multidetector helical CT. *J Oral Sci* 2006;48:27-34.
24. Ramamurthy R, Scheetz JP, Clark SJ, Farman AG. Effects of imaging system and exposure on accurate detection of the second mesio-buccal canal in maxillary molar teeth. *Oral Surg Oral Med Oral Pathol Oral Radiol Endod* 2006;102:796-802.
25. Tu MG, Tsai CC, Jou MJ, Chen WL, Chang YF, Chen SY, *et al.* Prevalence of three-rooted mandibular first molars among Taiwanese individuals. *J Endod* 2007;33:1163-6.
26. Zheng Q, Zhang L, Zhou X, Wang Q, Wang Y, Tang L, *et al.* C-shaped root canal system in mandibular second molars in a Chinese population evaluated by cone-beam computed tomography. *Int Endod J* 2011;44:857-62.
27. Estrela C, Bueno MR, Sousa-Neto MD, Pécora JD. Method for determination of root curvature radius using cone-beam computed tomography images. *Braz Dent J* 2008;19:114-8.
28. Matherne RP, Angelopoulos C, Kulild JC, Tira D. Use of cone-beam computed tomography to identify root canal systems *in vitro*. *J Endod* 2008;34:87-9.
29. Patel S. The use of cone beam computed tomography in the conservative management of dens invaginatus: A case report. *Int Endod J* 2010;43:707-13.
30. Das S, Warhadpande MM, Redij SA, Sabir H, Shirude T. Management of synodontia between dilacerated permanent maxillary central incisor and supernumerary tooth with aid of cone-beam computed tomography. *J Conserv Dent* 2015;18:163-7.
31. Huuonen S, Orstavik D. Radiological aspects of apical periodontitis. *Endod Top* 2002;1:3-25.
32. Estrela C, Bueno MR, Leles CR, Azevedo B, Azevedo JR. Accuracy of cone beam computed tomography and panoramic and periapical radiography for detection of apical periodontitis. *J Endod* 2008;34:273-9.
33. Low KM, Dula K, Bürgin W, von Arx T. Comparison of periapical radiography and limited cone-beam tomography in posterior maxillary teeth referred for apical surgery. *J Endod* 2008;34:557-62.
34. Patel S, Dawood A, Mannocci F, Wilson R, Pitt Ford T. Detection of periapical bone defects in human jaws using cone beam computed tomography and intraoral radiography. *Int Endod J* 2009;42:507-15.
35. Ahlowalia MS, Patel S, Anwar HM, Cama G, Austin RS, Wilson R, *et al.* Accuracy of CBCT for volumetric measurement of simulated periapical lesions. *Int Endod J* 2013;46:538-46.
36. Estrela C, Bueno MR, Azevedo BC, Azevedo JR, Pécora JD. A new periapical index based on cone beam computed tomography. *J Endod* 2008;34:1325-31.
37. Patel S, Wilson R, Dawood A, Foschi F, Mannocci F. The detection of periapical pathosis using digital periapical radiography and cone beam computed tomography – Part 2: A 1-year post-treatment follow-up. *Int Endod J* 2012;45:711-23.
38. Ball RL, Barbizam JV, Cohenca N. Intraoperative endodontic applications of cone-beam computed tomography. *J Endod* 2013;39:548-57.
39. Cohenca N, Simon JH, Roges R, Morag Y, Malfaz JM. Clinical indications for digital imaging in dento-alveolar trauma. Part 1: Traumatic injuries. *Dent Traumatol* 2007;23:95-104.

40. Tyndall DA, Rathore S. Cone-beam CT diagnostic applications: Caries, periodontal bone assessment, and endodontic applications. *Dent Clin North Am* 2008;52:825-41, vii.
41. Martos J, Silva FS, Poglia ID, Damian MF, Silveira LM. Influence of X-ray beam angulations on the detection of horizontal root fractures. *Saudi Endod J* 2015;5:129-33.
42. Farmakis ET, Damaskos S, Konstandinidis C. Cone beam computed tomography imaging as a diagnostic tool in determining root fracture in endodontically treated teeth. *Saudi Endod J* 2012;2:22-8.
43. Brady E, Mannocci F, Brown J, Wilson R, Patel S. A comparison of cone beam computed tomography and periapical radiography for the detection of vertical root fractures in nonendodontically treated teeth. *Int Endod J* 2014;47:735-46.
44. Hassan B, Metska ME, Ozok AR, van der Stelt P, Wesselink PR. Detection of vertical root fractures in endodontically treated teeth by a cone beam computed tomography scan. *J Endod* 2009;35:719-22.
45. Estrela C, Bueno MR, Goncalves AH, Mattar R, Neto JV, Azevedo BC, *et al.* Method to evaluate inflammatory root resorption by using cone beam computed tomography. *J Endod* 2009;35:1491-7.
46. Maini A, Durning P, Drage N. Resorption: Within or without? The benefit of cone-beam computed tomography when diagnosing a case of an internal/external resorption defect. *Br Dent J* 2008;204:135-7.
47. Vasconcelos Kde F, Nejaim Y, Haiter Neto F, Bóscolo FN. Diagnosis of invasive cervical resorption by using cone beam computed tomography: Report of two cases. *Braz Dent J* 2012;23:602-7.
48. Haghanifar S, Moudi E, Mesgarani A, Bijani A, Abbaszadeh N. A comparative study of cone-beam computed tomography and digital periapical radiography in detecting mandibular molars root perforations. *Imaging Sci Dent* 2014;44:115-9.
49. Paula-Silva FW, Wu MK, Leonardo MR, Bezerra LA, Wesselink PR. Accuracy of periapical radiography and cone-beam computed tomography scans in diagnosing apical periodontitis using histopathological findings as a gold standard. *J Endod* 2009;35:1009-12.
50. Rigolone M, Pasqualini D, Bianchi L, Berutti E, Bianchi SD. Vestibular surgical access to the palatine root of the superior first molar: "Low-dose cone-beam" CT analysis of the pathway and its anatomic variations. *J Endod* 2003;29:773-5.
51. Bornstein MM, Scarfe WC, Vaughn VM, Jacobs R. Cone beam computed tomography in implant dentistry: A systematic review focusing on guidelines, indications, and radiation dose risks. *Int J Oral Maxillofac Implants* 2014;29 (Suppl:55-77). [doi: 10.11607/jomi.2014suppl.g1.4].